

1 **Title:** Peroneal Nerve Injury due to Hip Surgery Located at the Knee Level: A Case Report

2
3 **Article type:** Case report

4
5 **Author names:**

- 6 1. Aleksa Mičić
7 2. Stefan Radojević
8 3. Lukas Rasulić

9
10 **Degrees and Affiliations:**

- 11 1. MD up to 3 months after graduation/Clinic for Neurosurgery, University Clinical Centre of Serbia,
12 Belgrade Serbia
13 2. MD up to 3 months after graduation/Clinic for Neurosurgery, University Clinical Centre of Serbia,
14 Belgrade Serbia
15 3. MD, Ph.D., Full Professor/Faculty of Medicine, University of Belgrade, Belgrade Serbia/Clinic for
16 Neurosurgery, University Clinical Centre of Serbia, Belgrade, Serbia

17 **ORCID (Open Researcher and Contributor Identifier):**

18 <https://orcid.org/0000-0001-5278-3834>

19 <https://orcid.org/0000-0002-8116-1599>

20 <https://orcid.org/0000-0003-3149-187X>

21
22 **About the author:** Aleksa Mičić is MD up to 3 months after graduation, currently engaged as an intern at the
23 University Clinical Centre of Serbia. He has 2 years of experience as an undergraduate research fellow at the
24 Department for Peripheral Nerve Surgery, Functional Neurosurgery, and Pain Management Surgery, Clinic for
25 Neurosurgery, University Clinical Centre of Serbia, and 7 years of experience as an associate at Petnica
26 Science Center.

27 **Corresponding author email:** aleksamicic.md@gmail.com

28 **Acknowledgment:** The authors would like to extend their sincere thanks to Andrija Savić MD, Ph.D. and Jovan
29 Grujić MD (Clinic for Neurosurgery, University Clinical Centre of Serbia, Serbia), Norma Izchel Orozco Aponte
30 MD (Clinica de Nervio Periférico en Puebla, Mexico), Jovan Vesic MD (Clinic for Orthopedic Surgery and
31 Traumatology, University Clinical Centre of Serbia, Serbia), and Milan Lepić MD, Ph.D. (Clinic for Neurosurgery,
32 Military Medical Academy) for continuous support and help during the writing of this article.

33 **Financing:** There were no grants, financial support, or any other contribution.

34 **Conflict of interest statement by authors:** The authors disclose no conflict of interest,

35 **Compliance with ethical standards:** All aspects of the work covered in this manuscript have been conducted
36 with the ethical approval of relevant bodies. The informed consent for publication was obtained from the patient.

37
38 **Authors Contribution Statement:** Aleksa Mičić: investigation, formal analysis, and writing; Stefan Radojević:
39 investigation; Lukas Rasulić: investigation, surgery, and supervision.

40 **Highlights**

- 41 • Peroneal nerve palsy is a rare complication of hip surgery.

- In a small number of cases, peroneal nerve palsy is a consequence of nerve injury at the knee level.
- There are only a few papers concerning the surgical management of these patients after the total hip arthroplasty (THA), while there are no thoroughly analyzed cases following open reduction and internal fixation (ORIF) of the acetabular fracture.
- This article presents a case of a surgically managed peroneal nerve injury located at the knee level consequential to the acetabular fracture ORIF.

Manuscript word count: 1355

Abstract word count: 229

Number of Figures and Tables: 3

Personal, Professional, and Institutional Social Network accounts.

- **Facebook:** <https://www.facebook.com/aleksamicicMD/>
- **Twitter:** <https://twitter.com/aleksamicicMD>
- **Linkedin:** <https://www.linkedin.com/in/aleksa-mičić-b90544111/>

Discussion Points:

- Is the ultrasound a necessary tool for preoperative planning and effective surgical management of patients with peroneal nerve injury following hip surgery?
- How orthopedic surgeons and anesthesiologists should be educated to avoid the occurrence of these injuries in the future? #MedicalStudents

Dates

Submission: 12/31/2022

Revisions: 01/25/2023

Responses: 03/07/2023

Acceptance: 03/08/2023

Publication: 03/27/2023

Editors

Associate Editor/Editor: Francisco J. Bonilla-Escobar

Student Editors:

Copyeditor:

Proofreader:

Layout Editor:

Publisher's Disclosure: *This is a PDF file of an unedited manuscript that has been accepted for publication. As a service to our readers and authors we are providing this early version of the manuscript. The manuscript will undergo copyediting, typesetting, and review of the resulting proof before it is published in its final citable form. Please note that during the production process errors may be discovered which could affect the content, and all legal disclaimers that apply to the journal pertain.*

1 **ABSTRACT.**

2 **Background:** A common peroneal nerve (CPN) injury located at the knee level, occurring as a consequence
3 of hip surgery is described in the literature. However, there are only a few papers concerning their surgical
4 management, while there are no thoroughly analyzed cases following open reduction and internal fixation
5 (ORIF) of the acetabular fracture. This paper aimed to describe a such case and discuss current trends in the
6 surgical management of these patients.

7 **The case:** A 32-year-old woman was admitted to our department due to left-sided CPN palsy. The patient was
8 injured in a traffic accident eight months earlier, followed by left hip dislocation and acetabular fracture. Following
9 the acetabular fracture ORIF, a CPN palsy developed. The electromyoneurography (EMNG) and ultrasound
10 (US) indicated a nerve lesion at the knee level. The surgical treatment included external neurolysis,
11 decompression, and complete nerve deliberation, with the preservation of all nerve branches. The patient
12 reported immediate relief, while completely recovered 8 months following the surgery (Medical Research
13 Council (MRC) grade = 5, Visual Analogous Scale (VAS) = 0).

14 **Conclusion:** The cause of CPN palsy following hip surgery may not always be located in the hip region. A
15 detailed anamnesis, physical examination, and diagnostic evaluation are necessary for the proper surgical
16 management of these patients. In addition to the EMNG, the US should be essential in preoperative planning
17 and choosing the most effective surgical strategy.

18
19
20

Accepted, in press

1 **INTRODUCTION.**

2

3 Peroneal nerve dysfunction often referred to as common peroneal nerve (CPN) palsy presents a functional
4 deficit, characterized by an inability to dorsiflex the foot (foot drop) with consequential disability and a significant
5 decrease in patients' quality of life.¹⁻³ The cause of dysfunction may lay in central nerve structures, spinal nerve
6 roots, sacral plexus, sciatic nerve (SN), the CPN, or its deep branch.⁴

7

8 The incidence of CPN palsy following the most common procedure in hip surgery – the total hip arthroplasty
9 (THA) ranged up to 8%, depending on the inclusion and exclusion criteria of the reviewed studies.⁵⁻⁷ In most
10 cases, the cause of the palsy involves SN injury at the hip region and may be a result of various etiologies, such
11 as direct nerve injury, excessive nerve stretch, postoperative hematoma, or infection.⁷ Rarely, the palsy may
12 develop as a consequence of CPN injury at the knee level, and there are only a few papers concerning their
13 surgical management,^{8,9} with a recently reported incidence of 0.48%.¹⁰

14

15 The open reduction and internal fixation (ORIF) of the acetabular fracture is performed less often than the THA,
16 thus the associated CPN injuries at the knee level are extremely rare.^{11, 12} To the best of our knowledge, a
17 thoroughly analyzed case of surgical treatment of such injury is not reported in the English medical literature.
18 This paper aimed to describe a such case and discuss current trends in the surgical management of these
19 patients.

20

21

Accepted, improved

1 THE CASE

2 A 32-year-old woman was admitted to our department due to left-sided CPN palsy. The patient was injured in
3 a traffic accident eight months before, followed by left hip dislocation and acetabular fracture. After admission
4 to the emergency care unit, the hip dislocation was repositioned. Two weeks later, ORIF of the acetabular
5 fracture was performed resulting in ipsilateral CPN palsy.

6 At the admission to our department, clinical findings included left-sided incomplete CPN palsy (Medical
7 Research Council (MRC) grade 2), pain in the lateral lower leg (Visual Analogue Scale (VAS) score 3), and gait
8 disturbances. Using electromyoneurography (EMNG), the peroneal nerve lesion was located at the knee level.
9 Reduced nerve conduction was noted in the tibialis anterior (TA) and extensor digitorum brevis (EDB) muscles,
10 while there were no changes in the short head of the biceps femoris (shBF) and muscles innervated by the tibial
11 nerve. The ultrasound (US) finding indicated a suspectable CPN compression due to visible nerve thickening
12 proximally to the fibular tunnel. The PNSQoL and SF-36 scores indicated a significant decline in the patient's
13 quality of life.

14 Following GETA, the external neurolysis, decompression, and complete nerve deliberation were performed
15 through the popliteal approach, with the preservation of all nerve branches (**Figure 1**). The nerve was thinned
16 at the site of the previous compression. There were no signs of nerve bruising.

17 The patient reported immediate relief following the surgery. 2 months after the surgery, there were signs of
18 motor recovery, with the improvement of foot dorsiflexion and gait performance. 3 months after the surgery, a
19 significant motor recovery was noted with insignificant gait disturbances mostly due to pain. A complete motor
20 and sensory recovery was achieved 8 months following the surgery (MRC = 5, VAS = 0). In order to assess
21 the patient's postoperative quality of life, a prolonged follow-up is needed.

22

1 DISCUSSION.

2
3 Surgical treatment of CPN palsy following trauma and associated orthopedic interventions must be planned
4 well, due to the various mechanisms of injury and different locations at which the nerve may be damaged.
5 Contrary to compression injuries which are easily managed by a simple surgical decompression, injuries due to
6 traction or contusion may require more complex procedures such as tendon transfer or nerve repair.³

7
8 Knowing the exact time of the nerve injury is important for determining the most effective surgical strategy, in
9 terms of choosing the most appropriate procedure and setting the timing for surgery.^{3, 13, 14} While surgical
10 decompression is indicated after 3 months of conservative management without the signs of motor recovery,
11 the nerve repair should not be performed later than 12 months following the injury. On the other hand, tendon
12 transfers are reserved for cases with poor recovery capacity due to extensive nerve injury or due to exceeding
13 the timing for nerve repair.³

14
15 Based on our experience,^{3, 13, 14} in some cases it is difficult to determine if the injury is acquired during the
16 trauma or during the orthopedic intervention because the patient is immobilized and unaware of the present
17 deficit. Regarding the patient described in this paper, the hip dislocation and its repositioning could have been
18 a cause of the palsy due to the traction and contusion of the SN.¹⁵ However, this was not the case. During the
19 period between the trauma and the performed ORIF, both the patient and the medical staff were aware of the
20 preserved CPN function and reported the palsy immediately following the intervention.

21
22 We could not provide the surgery for the patient when it was indicated because she was recovering for a long
23 time after the trauma and came to our clinic for evaluation 7 months later. Even though, it seems that the timing
24 was not a factor that affected the outcome of our patient which is in accordance with a similar case that occurred
25 following the THA.⁸ In their paper, the authors performed CPN decompression 8 months following the injury and
26 achieved almost complete motor recovery. A poorer recovery in their patient compared to ours may be a
27 consequence of a more serious CPN damage or a different decompression procedure that was used.

28
29 Similar to the study by Wilson et al⁹, we used the EMNG to detect a reduced CPN conduction and locate the
30 nerve lesion at the knee level. However, in their study 22% of the patients had no motor unit potentials (MUPs)
31 in the short head of the biceps femoris muscle (BFsh), indicating that the lesion may be extended proximally in
32 relation to the fibular tunnel.¹⁶ Even though there was a tendency for better outcomes in those who had the
33 BFsh MUPs, the CPN decompression had positive effects on motor recovery in some of the cases with reduced
34 BFsh MUPs.⁹ Regarding our patient, there was no reduction in the BFsh MUPs, and complete motor recovery
35 was achieved. Therefore, a simultaneous CPN and SN injury should be considered in cases that fail to
36 recover.¹⁷

37
38 Compared to EMNG, the US is more precise in determining the exact location of the nerve injury, while in
39 comparison to magnetic resonance imaging (MRI), it has a higher sensitivity in detecting peripheral nerve
40 pathology and understanding the mechanism of injury.¹⁷ Thus, the US plays a very important role in diagnosing
41 and managing the patients with peripheral nerve injuries. It was already discussed in the literature that a CPN

1 palsy following the acetabular fracture ORIF,¹¹ usually performed in the Cocker-Lagenback position (**Figure 2**),
2 may be a consequence of SN traction by the retractors and consequential CPN compression due to its reduced
3 mobility at the fibular tunnel. This mechanism may be applied to our patient considering the US finding that
4 revealed nerve thickening proximally to the fibular tunnel and intraoperative finding of the nerve (**Figure 1**) which
5 was thinned at the site of the previous compression.

6
7 Compared to the aforementioned mechanism of CPN injury following the acetabular fracture ORIF, there are
8 some differences in cases that occur following THA. In a posterior approach for THA,¹⁸ the SN is often
9 visualized, and its traction may result in CPN compression at the fibular tunnel. However, in THA procedures in
10 which the SN is not visualized¹⁹, such as the Smith Petersen and Watson Jones approach, the cause of the
11 CPN injury is probably SN stretching due to leg manipulation (**Figure 3**). Compared to the SN stretching by the
12 retractors, in cases with leg manipulation the length of the nerve stretch may be longer, resulting in more serious
13 CPN entrapment or even a traction injury. In their study,⁹ Wilson et al. did not use the US to confirm isolated
14 CPN entrapment and to differentiate cases with traction injury. This may be the factor influencing poorer
15 postoperative recovery in some of their patients and indicates the importance of US usage in the preoperative
16 evaluation of such cases.

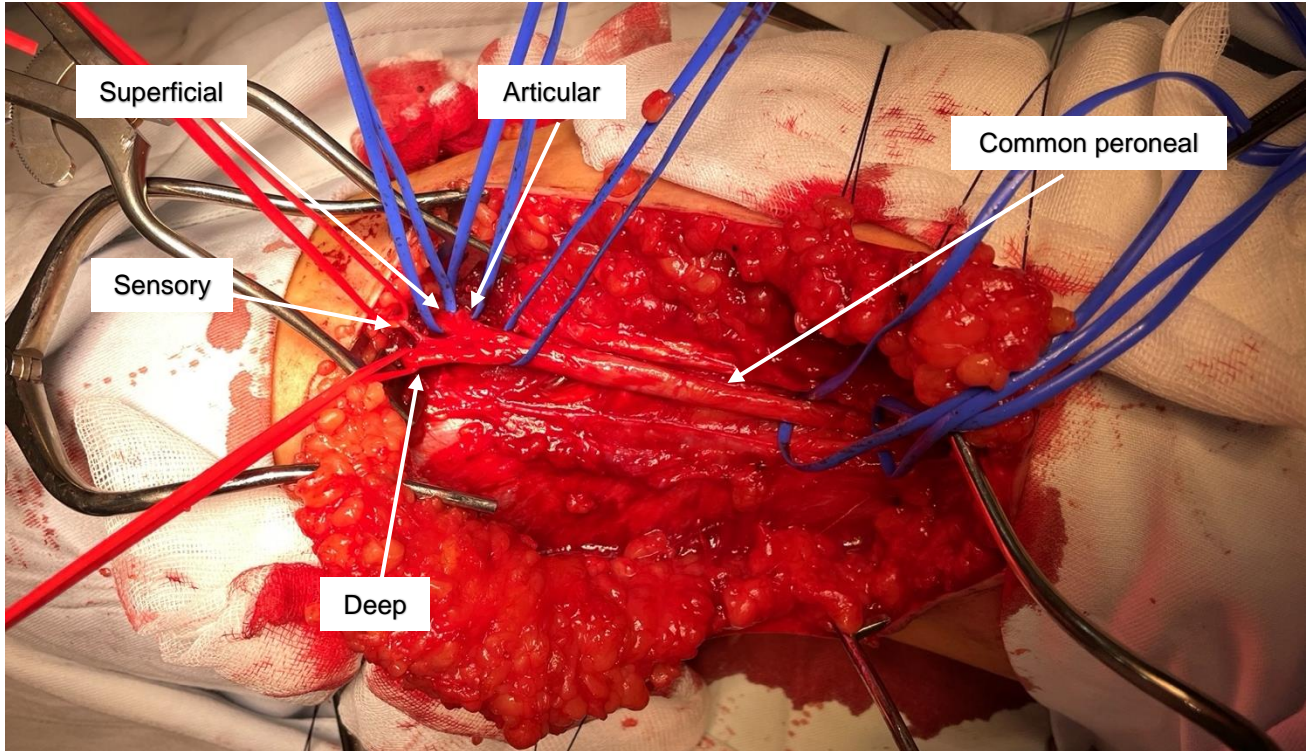
17
Accepted, in-press

1 REFERENCES.

- 2
- 3 1. Aprile I, Caliandro P, La Torre G, Tonali P, Foschini M, Mondelli M, et al. Multicenter study
4 of peroneal mononeuropathy: clinical, neurophysiologic, and quality of life assessment. *J Peripher*
5 *Nerv Syst.* 2005;10(3):259-68.
 - 6 2. Poage C, Roth C, Scott B. Peroneal Nerve Palsy: Evaluation and Management. *JAAOS -*
7 *Journal of the American Academy of Orthopaedic Surgeons.* 2016;24(1):1-10.
 - 8 3. Rasulić L, Nikolić Ž, Lepić M, Savić A, Vitošević F, Novaković N, et al. Useful functional
9 recovery and quality of life after surgical treatment of peroneal nerve injuries. *Front Surg.*
10 2022;9:1005483.
 - 11 4. Carolus AE, Becker M, Cuny J, Smektala R, Schmieder K, Brenke C. The Interdisciplinary
12 Management of Foot Drop. *Dtsch Arztebl Int.* 2019;116(20):347-54.
 - 13 5. Park JH, Hozack B, Kim P, Norton R, Mandel S, Restrepo C, et al. Common peroneal nerve
14 palsy following total hip arthroplasty: prognostic factors for recovery. *J Bone Joint Surg Am.*
15 2013;95(9):e55.
 - 16 6. Zappe B, Glauser PM, Majewski M, Stöckli HR, Ochsner PE. Long-term prognosis of nerve
17 palsy after total hip arthroplasty: results of two-year-follow-ups and long-term results after a mean
18 time of 8 years. *Archives of Orthopaedic and Trauma Surgery.* 2014;134(10):1477-82.
 - 19 7. Hasija R, Kelly JJ, Shah NV, Newman JM, Chan JJ, Robinson J, et al. Nerve injuries associated
20 with total hip arthroplasty. *J Clin Orthop Trauma.* 2018;9(1):81-6.
 - 21 8. Makhdom AM. Common Peroneal Nerve Palsy at the Level of Proximal Fibula After Total
22 Hip Arthroplasty: A Case Report. *Cureus.* 2022;14(10):e30741.
 - 23 9. Wilson TJ, Kleiber GM, Nunley RM, Mackinnon SE, Spinner RJ. Distal peroneal nerve
24 decompression after sciatic nerve injury secondary to total hip arthroplasty. *J Neurosurg.*
25 2018;130(1):179-83.
 - 26 10. Georgeanu VA, Russu OM, Obada B, Iliescu MG, Popescu MN, Iliescu DM, et al. Common
27 peroneal nerve palsy after primary total hip arthroplasty. *Int Orthop.* 2022;46(9):1963-70.
 - 28 11. Simske NM, Krebs JC, Heimke IM, Scarcella NR, Vallier HA. Nerve Injury With Acetabulum
29 Fractures: Incidence and Factors Affecting Recovery. *J Orthop Trauma.* 2019;33(12):628-34.
 - 30 12. Ramanan M, Chandran KN. Common peroneal nerve decompression. *ANZ J Surg.*
31 2011;81(10):707-12.
 - 32 13. Rasulić L, Djurašković S, Lakićević N, Lepić M, Savić A, Grujić J, et al. Surgical Treatment
33 of Radial Nerve Injuries Associated With Humeral Shaft Fracture—A Single Center Experience.
34 *Frontiers in Surgery.* 2021;8.
 - 35 14. Rasulić L, Đjurašković S, Lakićević N, Lepić M, Savić A, Grujić J, et al. Etiological and
36 epidemiological characteristics of surgically treated radial nerve lesions: A 20-year single-center
37 experience. *Frontiers in Surgery.* 2022;9.
 - 38 15. Cornwall R, Radomisli TE. Nerve Injury in Traumatic Dislocation of the Hip. *Clinical*
39 *Orthopaedics and Related Research®.* 2000;377:84-91.
 - 40 16. Thatte H, De Jesus O. Electrodiagnostic Evaluation Of Peroneal Neuropathy. *StatPearls.*
41 *Treasure Island (FL): StatPearls Publishing*
42 *Copyright © 2022, StatPearls Publishing LLC.; 2022.*
 - 43 17. Wijntjes J, Borchert A, van Alfen N. Nerve Ultrasound in Traumatic and Iatrogenic Peripheral
44 Nerve Injury. *Diagnostics (Basel).* 2020;11(1).
 - 45 18. Angerame MR, Dennis DA. Surgical approaches for total hip arthroplasty. *Annals of Joint.*
46 2018;3(5).
 - 47 19. Weale AE, Newman P, Ferguson IT, Bannister GC. Nerve injury after posterior and direct
48 lateral approaches for hip replacement. A clinical and electrophysiological study. *J Bone Joint Surg*
49 *Br.* 1996;78(6):899-902.
- 50

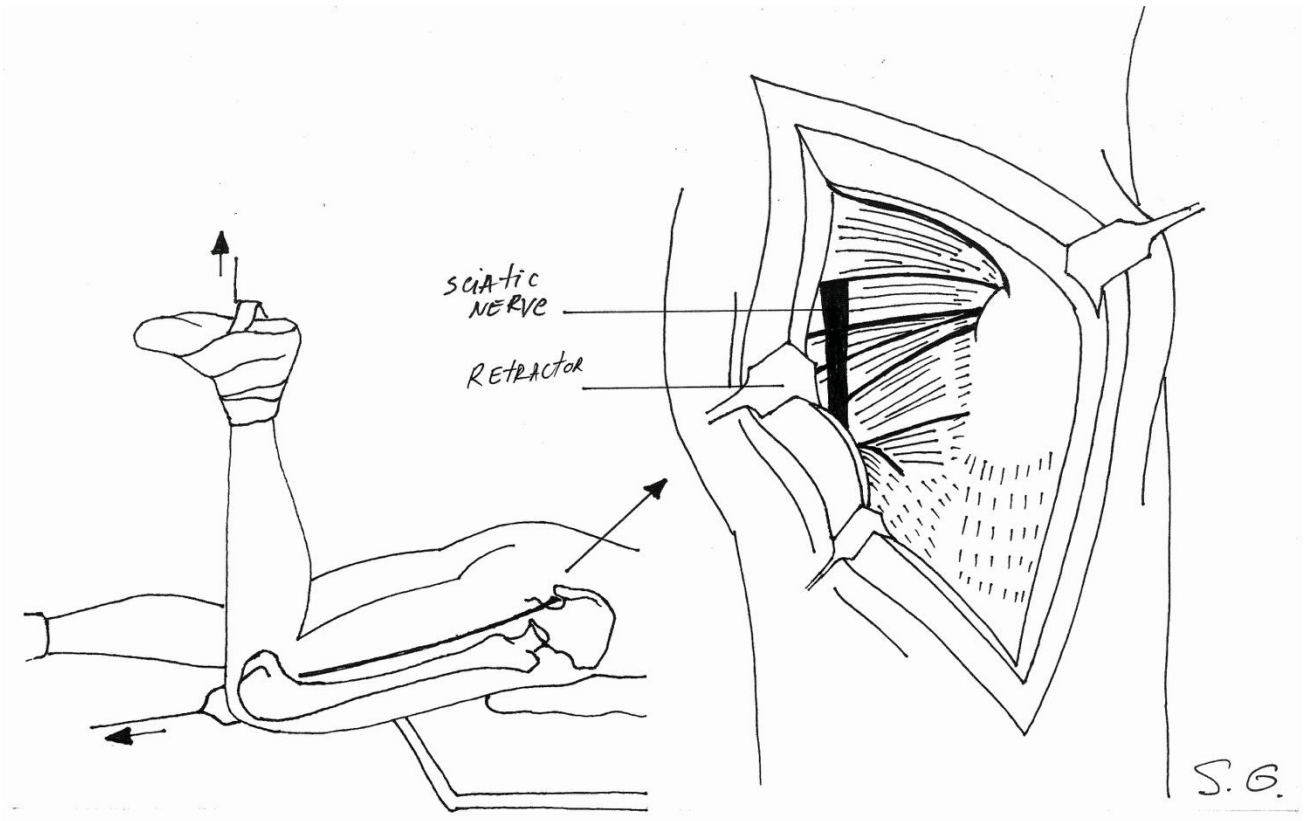
1 **FIGURES AND TABLES.**

2
3 **Figure 1.** Intraoperative Picture of the Common Peroneal Nerve (CPN) with its Terminal and Side Branches
4 after External Neurolysis, Decompression, and Complete Nerve Deliberation.



23
24 **Figure 2.** Drawing to Present the Proximity of the Sciatic nerve to the Retractors during the Acetabular Fracture
25 ORIF Performed in the Cocker-Lagenback Position, with Courtesy of Strahinja Gligorijević. Flexion of the Knee
26 is a Measure for preventing the associated CPN injury.

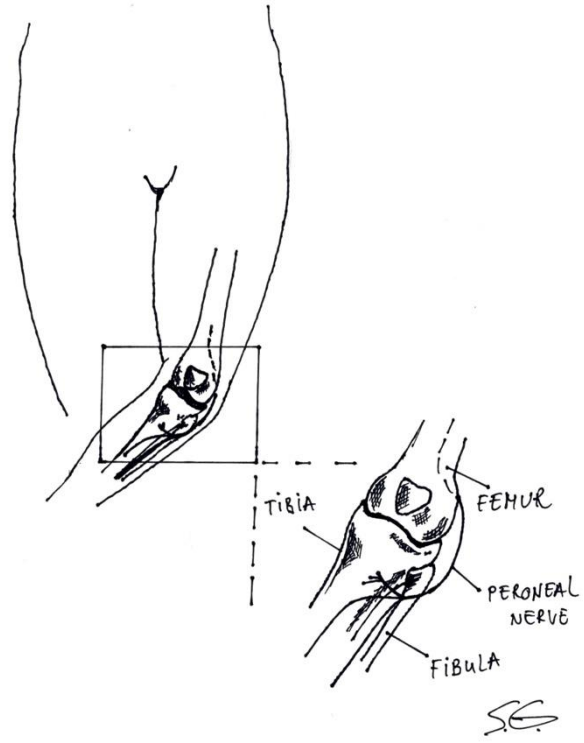
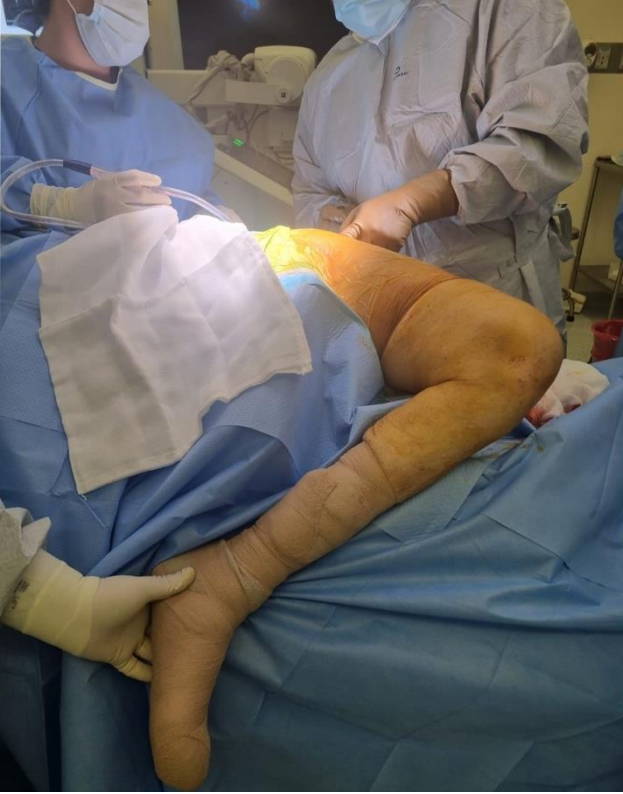Accepted



1
2
3
4
5
6
7

Figure 3. Leg Manipulation during the Antero-Lateral Approaches for Total Hip Arthroplasty (THA): (A) Intraoperative picture, with courtesy of dr Norma Izchel Orozco Aponte; (B) Drawing with Courtesy of Strahinja Gligorijević.

Accepted



1

Accepted, 11