

# Pulmonary Thromboembolism in Multidrug-Resistant Tuberculosis: A Case Series Highlighting the Importance of Early Diagnosis and Management

Vikas Marwah,<sup>1</sup> Gaurav Bhati,<sup>2</sup> Robin Choudhary,<sup>3</sup> Anmol Sharma.<sup>4</sup>

## Abstract

**Background:** Pulmonary tuberculosis (PTB) is an established cause of arterial and venous thrombosis. With the rising incidence of multidrug-resistant tuberculosis (MDR TB), which has a prolonged treatment course, pulmonary thromboembolism in such cases further complicates the treatment outcome in terms of mortality and morbidity. TB causes systemic hypercoagulability, which may lead to both arterial and venous thrombosis. Therefore, it is important for treating physicians to be aware of the entity and have a sharp watch for the development of Pulmonary thromboembolism in cases of MDR TB. **The Case:** We present the association of pulmonary thromboembolism (PTE) with MDR TB in three young males who developed pulmonary thromboembolism during the treatment of MDR TB, along with their management using anticoagulant agents. **Conclusion:** PTE in cases of TB is rare but fatal. High suspicion of PTE in patients with MDR TB will help in diagnosing the dreaded condition early and aid in reducing preventable mortality with PTE. Early recognition, prompt diagnosis, and management is the key to saving the lives of those with this fatal complication.

## Introduction

More than 25% of the global burden of tuberculosis (TB) is seen in low and middle income countries like India with an estimated 27 lakh patients as per Global TB Report 2020.<sup>1</sup> The incidence of multidrug-resistant tuberculosis/rifampicin-resistant tuberculosis (MDR-TB/RR) is 11 per lakh of the Indian population and will keep on increasing in the future.

TB is known to affect the coagulation parameters of the body.<sup>2</sup> Identifying the patients who are at high risk of developing venous thromboembolism and meticulous planning of their chemotherapy consisting of anti-tuberculous medications and anticoagulants becomes of paramount importance to avoid adverse outcomes. Patients with acute infections are 2-10 times more prone to develop venous thromboembolism (VTE) as compared to the normal population<sup>3</sup>. VTE is also known to complicate chronic infections like tuberculosis, affecting around 3-4 % of these patients and the estimated percentage can be higher since most cases are subclinical and are never diagnosed.<sup>4</sup>

The study aimed to highlight the likely and often missed complication of pulmonary thromboembolism in cases of tuberculosis and to increase awareness among the treating

## Highlights:

- Tuberculosis itself poses as a hypercoagulable state and poses a risk for deep vein thrombosis and venous pulmonary thromboembolism.
- Physicians treating tuberculosis must be aware and alert regarding this uncommon yet fatal complication of tuberculosis and have a keep clinical eye to diagnose thrombosis at earliest.
- Early diagnosis and management with anticoagulation and fibrinolysis when required is the key to limit the mortality and morbidity associated with this disease.

physicians as a differential of pulmonary thromboembolism while managing a case of TB. We report three cases of MDR pulmonary tuberculosis manifesting with massive and sub-massive pulmonary thromboembolism (PTE) with no prior apparent risk factors before illness. This study is important for physicians managing MDR TB to be aware of PTE as a complication and take prompt action toward early diagnosis and treatment of this potentially fatal clinical entity.

<sup>1</sup> MD (Pulmonary Medicine), Senior Consultant, Dept of Pulmonary, Critical care and sleep medicine, AICTS, Pune, India.

<sup>2</sup> MD (Pulmonary Medicine), Senior resident, Dept of Pulmonary, Critical Care and Sleep Medicine, AICTS, Pune, India.

<sup>3</sup> MD (Pulmonary Medicine), Consultant, Dept of Pulmonary, Critical care and sleep medicine, Base Hospital Delhi Cantt, New Delhi, India.

<sup>4</sup> MBBS, Resident Internal Medicine, Base Hospital Delhi Cantt, India.

**About the Author:** Dr. Anmol Sharma is currently pursuing his post-graduation in General medicine at Base Hospital Delhi Cantt, New Delhi India as part of a 3-year program. He is the recipient of ICMR Studentship and has won awards for best papers at various conferences.

## Correspondence:

Robin Choudhary.

Address: Maude Road, Near Bank Of India, Delli Cantt, Delhi 110010.

Email: [robinch19@gmail.com](mailto:robinch19@gmail.com)

Editor: Francisco J. Bonilla-Escobar  
Student Editors: Joseph Tonge, Sebastian Diebel & Jonaviva Thomas  
Proofreader: Amy Phelan  
Layout Editor: Ana Maria Morales

Submission: Apr 5, 2022  
Revisions: Jun 12, Aug 6 2023  
Responses: Jun 28, Aug 30 2023  
Acceptance: Sep 11, 2023  
Publication: Dec 13, 2023  
Process: Peer-reviewed

## The Case

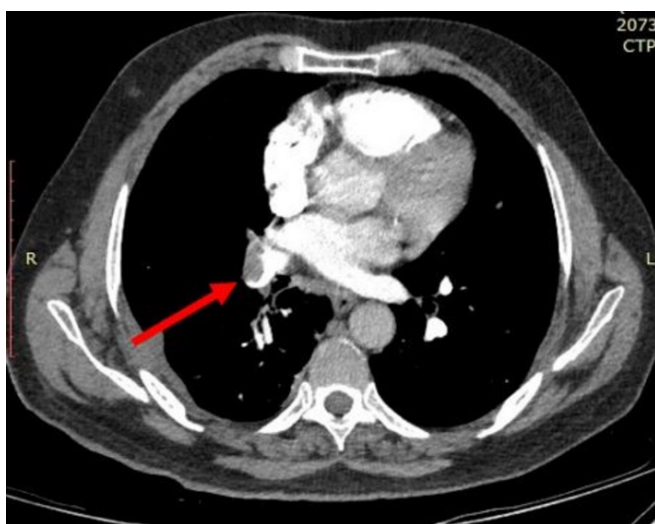
### Case 1

A 21-year-old male, a nonsmoker reported complaints of breathlessness, fever, cough, right-sided pleuritic chest pain, and loss of appetite of 10 days duration. His chest radiograph showed right-sided upper lobe consolidation and pleural effusion, diagnostic pleurocentesis of which revealed exudative, lymphocyte-predominant fluid with high adenosine deaminase (ADA). The patient was found to be sputum smear positive for acid-fast bacilli (AFB) and cartridge-based nucleic acid amplification test (CBNAAT) was suggestive of rifampicin resistance. He was started on anti-tubercular drugs, however, he started to have breathlessness on exertion. He underwent computed tomography pulmonary angiography which revealed thrombo-embolism in the right pulmonary trunk as shown in [Figure 1](#). The patient was started on low molecular weight heparin at 60 mcg twice a day and later switched to tab dabigatran 150 mg BD after 5 days along with second-line antituberculous therapy (ATT) to which he showed a favorable response and gradually improved. Dabigatran was stopped after 6 months, and a thrombophilia workup was done which was negative.

### Case 2

A 35-year-old healthy male presented with complaints of fever, dry cough, and progressive breathlessness (MMRC II to III) along with a weight loss of two kilograms over two months. On evaluation, chest radiograph and contrast-enhanced computed tomography of the chest were suggestive of right-sided pleural effusion as shown in [Figure 2](#). Pleural fluid analysis revealed lymphocyte-predominant, exudative effusion with ADA of 58 IU/ml. The patient was diagnosed with tuberculous pleural effusion and was started on first-line anti-tubercular therapy (ATT) comprising Tab isoniazid 300mg, rifampicin 600 mg, pyrazinamide 1500 mg, and ethambutol 1200 mg OD (once a day).

**Figure 1.** CT Pulmonary Angiogram Showing Thrombo-Embolism in the Right Pulmonary Trunk.

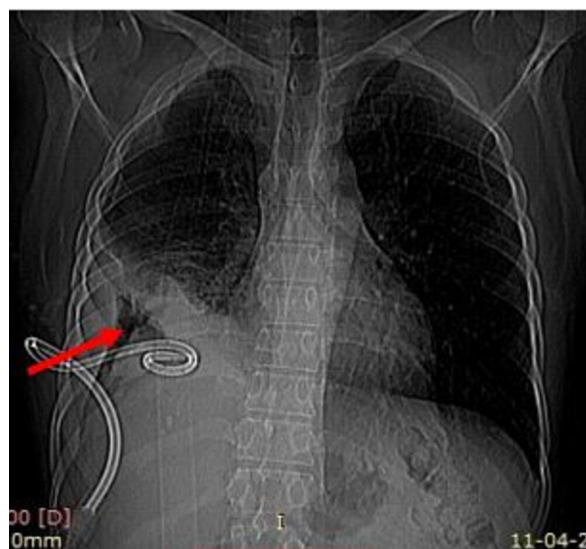


The patient had completed two months of anti-tubercular therapy when he suddenly had acute onset breathlessness of one-day duration with hemodynamic collapse. The patient had sudden cardiac arrest and cardiopulmonary resuscitation (CPR) was started immediately. The patient was thrombolysed with 50 mg of recombinant tissue plasminogen activator (r-TPA) and was intubated and placed on mechanical ventilation. He improved clinically but developed acute kidney injury, hematuria, and upper gastrointestinal hemorrhage, which was managed with pantoprazole infusion (80 mg stat followed by 8 mg/h infusion) along with hemodialysis, with which the kidney function recovered. He was continued on Injection heparin 5000 U BD. Subsequently patient was diagnosed to have loculated effusion on the right side of the chest and diagnostic pleurocentesis which revealed exudative fluid with positive pleural fluid mycobacterium tuberculosis (MTB) culture. A line probe assay done on culture specimens showed resistance to rifampicin and isoniazid. Patient was diagnosed as multidrug-resistant tuberculous pleural effusion and was treated with an MDR TB regimen (Tab bedaquiline 400 mg QD for 2 weeks followed by 200 mg thrice weekly, Tab levofloxacin 750 mg OD, Tab linezolid 600 mg OD, Tab Ccofazamine 100 mg OD, Tab cycloserine 750 mg OD) and tab apixaban 5 mg BD with which he gradually improved. Thrombophilia work-up done after three months was negative.

### Case 3

A 27-year-old male presented with complaints of cough, pleuritic chest pain, weight loss of four to five kilograms over six months along with intermittent fever with evening fever of one-week duration. On evaluation, the patient had bilateral pleural effusion on the chest radiograph. Computed tomography pulmonary angiography revealed thromboembolism in the right main pulmonary trunk along with a few centrilobular nodules in the right upper lobe and right lower lobe, bilateral pleural effusion, and a cold abscess over the right third rib as shown in [Figure 3](#).

**Figure 2.** CXR PA View Showing Right-Sided Pleural Effusion with a Pigtail in Situ.



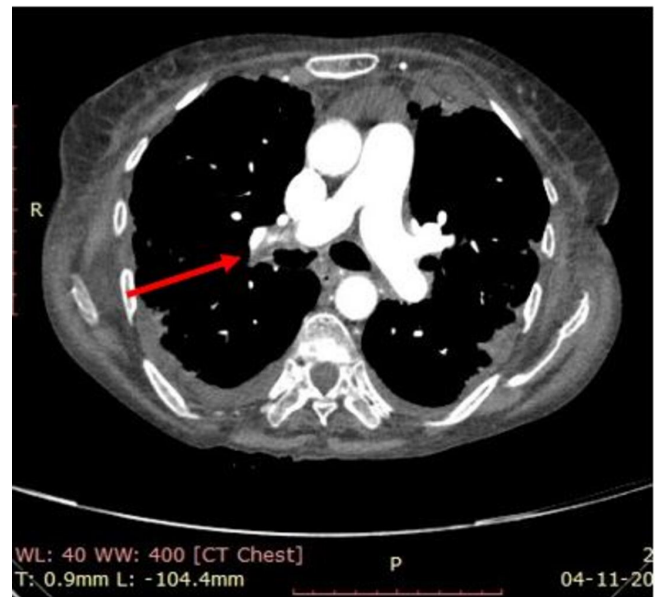
The patient was diagnosed to have disseminated tuberculosis (pleuro-pulmonary and bone involvement), CBNAAT of pus aspirate from cold abscess revealed MTB along with rifampicin resistance. The patient was started on an MDR regimen along with oral Rivaroxaban 2.5 mg BD. Gradually patient improved and was subsequently treated with rivaroxaban for six months and anti-tuberculous therapy was continued for 18 months. Thrombophilia workup was done after rivaroxaban was stopped and it came back negative. We also did a color doppler of the lower limb of all three patients which was normal.

## Discussion

Venous thrombosis is frequently associated with recurrent thromboembolism which can also be fatal.<sup>5</sup> Tuberculosis can result in a transient hypercoagulable state with thrombocytosis, increased fibrinogen, factor VIII, plasminogen activator inhibitor 1 plasma levels; a decline in antithrombin III and protein C and S levels leading to activation of coagulation cascade and suppression of fibrinolytic pathway.<sup>6,8</sup> Mycobacterium tuberculosis bacillus also promotes direct endothelial damage which aggravates the development of thrombus.<sup>7</sup> Production of pro-inflammatory cytokines (interleukin 1, interleukin, tumor necrosis factor  $\alpha$ ) in response to mycobacterial products also results in a hypercoagulable state.<sup>9,10</sup> Lymphadenopathy seen frequently in these patients can also cause mechanical compression of adjacent blood vessels leading to stasis and finally thrombosis.<sup>11</sup> Rifampin also has been implicated in the development of venous thrombosis and because of its enzyme-inducing effect, a higher dose of oral anticoagulants is frequently needed to achieve therapeutic INR levels.<sup>12</sup>

On review of Indian literature, we could identify various case reports of pulmonary TB along with documented deep venous thrombosis. whereas the association of TB along with PTE has been reported in fewer cases.<sup>13-17</sup> Mohan B, et al reported the largest case series from India with 5 cases of pulmonary embolism, in which all the five cases were males and with age less than 47 years. In our study, all the cases were young males out of which two cases had primary pleuro-pulmonary MDR tuberculosis while one had primary pulmonary MDR tuberculosis. Thrombolysis was warranted in only one of our patients as he developed hypoxia, hypotension, and cardiac arrest requiring mechanical ventilation while the other two cases were diagnosed based on out-of-proportion tachycardia and breathlessness on exertion and were managed with low molecular weight heparin initially and oral anticoagulants later. In our study, two patients had breathlessness as the main presenting symptom with a relatively short duration of illness before reporting at a medical facility and their dyspnea was disproportionate to the pulmonary lesions seen on the chest radiograph, along with a short history which raised the suspicion for pulmonary thromboembolism. These patients were all healthy young individuals with no prior risk factors for pulmonary thromboembolism apart from MDR tuberculosis.<sup>14</sup>

**Figure 3.** Computed Tomography Pulmonary Angiography Revealed Thromboembolism in the Right Main Pulmonary Trunk Along with a Few Centrilobular Nodules in the Right Upper Lobe and Right Lower Lobe and Bilateral Pleural Effusion.



**Table 1.** Indian Case Series and Case Reports of Deep Vein Thrombosis Associated with Tuberculosis.

Author	Type of Study	Year	No of cases	Modality used for diagnosis	Treatment	Diagnosis VTE/PTE
Gogna A <sup>11</sup>	Case report	1999	2	Venous doppler, CECT abdomen	LMWH	VTE
Naithan i R et al <sup>13</sup>	Case report	2007	1	Venous Doppler	LMWH+ Warfarin	DVT
Sharma et al <sup>14</sup>	Case report	2007	1	Venous Doppler USG	Unfractionated heparin + warfarin	DVT
Kumar et al <sup>12</sup>	Case report	2011	1	Venous Doppler	Unfractionated heparin + warfarin	DVT
Shah et al <sup>15</sup>	Case report	2011	1	Venous Doppler	Enoxaparin + warfarin	DVT
Mohan B et al <sup>16</sup>	Case report	2011	5	Venous Doppler and CT	Streptokinase + urokinase + heparin	PTE
Muley et al <sup>18</sup>	Case report	2014	2	Venous Doppler USG	Unfractionated Heparin + warfarin	DVT
Sangani et al <sup>17</sup>	Case report	2015	1	Venous Doppler USG	Enoxaparin + warfarin	DVT

Our study is the index case series from India of MDR TB cases complicated by PTE. It is also reiterated that our patients developed PTE despite there being no clinical or radiological evidence of DVT. In two of our cases, MDR TB was diagnosed on CBNAAT at presentation. Thus, it is important to identify that MDR TB can be a risk factor for developing PTE and if there is a clinical suspicion of the same then these patients should be actively evaluated, and they should be started on therapeutic anticoagulation till the diagnosis has been ruled out. PTE can be life-threatening so the index of suspicion should be high in these patients to prevent unnecessary mortality. The review of Indian literature of case reports and case series documenting PE with tuberculosis has been shown in [Table 1](#). Case reports of pulmonary tuberculosis along with venous thromboembolism have been reported from India, among these very few had pulmonary thromboembolism.

The association of pulmonary thromboembolism (PTE) with MDR TB has not been reported in India. We report three cases of this under-recognized association where timely diagnosis was life-saving. High suspicion of PTE in patients with MDR TB will help in

diagnosing the dreaded condition early and aid in reducing preventable mortality.

## Summary – Accelerating Translation

**Title-** Pulmonary Thromboembolism in Multidrug-Resistant Tuberculosis: A Case Series Highlighting the Importance of Early Diagnosis and Management.

**Main Problem to solve-** Pulmonary Tuberculosis is a common disease worldwide and the cases of Multidrug resistance are on the increasing trend. These patients are at a higher risk of developing pulmonary thromboembolism which increases the mortality and morbidity in them. The methodology aim of this retrospective observational study was to highlight this important entity for all the clinicians treating such cases. In our study, these three cases of young males who were diagnosed with Multidrug resistance Tuberculosis developed Pulmonary thromboembolism.

**Results and conclusion** were treated with MDR TB drugs and anticoagulation. Patients with MDR Tuberculosis are predisposed to Pulmonary thromboembolism and its diagnosis requires a high index of suspicion and should be promptly treated to reduce mortality.

## References

- Chakaya J, Khan M, Ntoumi F, Aklillu E, Fatima R, Mwaba P, Kapata N, Mfinanga S, Hasnain SE, Katoto PD, Bulabula AN. Global Tuberculosis Report 2020—Reflections on the Global TB burden, treatment and prevention efforts. *Int J Infect Dis*. 2021;113:S7-S12.
- Prasad R, Gupta N, Banka A. Multidrug-resistant tuberculosis/rifampicin-resistant tuberculosis: Principles of management. *Lung India*. 2018;35(1):78-81.
- Rogers MA, Levine DA, Blumberg N, Flanders SA, Chopra V, Langa KM. Triggers of hospitalization for venous thromboembolism. *Circulation*. 2012;125(17):2092-9.
- Hirsh J, Hoak J. Management of deep vein thrombosis and pulmonary embolism: a statement for healthcare professionals from the council on thrombosis (in consultation with the council on cardiovascular radiology), American Heart Association. *Circulation*. 1996;93(12):2212-45.
- Prandoni P, Bernardi E, Marchiori A, Lensing AW, Prins MH, Villalta S, Bagatella P, Sartor D, Piccoli A, Simioni P, Pagnan A. The long-term clinical course of acute deep vein thrombosis of the arm: prospective cohort study. *BMJ*. 2004;329(7464):484-5.
- Robson SC, White NW, Aronson I, Woollgar R, Goodman H, Jacobs P. Acute-phase response and the hypercoagulable state in pulmonary tuberculosis. *Br J Haematol*. 1996;93(4):943-9.
- Aguirre B, ME AS. Tuberculosis as a risk factor for venous thrombosis. *Am Med Interna*. 1993;10(8):398-400.
- Ambrosetti M, Ferrarese M, Codecasa LR, Besozzi G, Sarassi A, Viggiani P, Migliori GB. Incidence of venous thromboembolism in tuberculosis patients. *Respiration*. 2006;73(3):396.
- Ogawa T, Uchida H, Kusumoto Y, Mori Y, Yamamura Y, Hamada S. Increase in tumor necrosis factor alpha-and interleukin-6-secreting cells in peripheral blood mononuclear cells from subjects infected with *Mycobacterium tuberculosis*. *Infect Immun*. 1991;59(9):3021-5.
- Gauldie J, Northemann W, Fey GH. IL-6 functions as an exocrine hormone in inflammation. Hepatocytes undergoing acute phase responses require exogenous IL-6. *J Immunol*. 1990;144(10):3804-8.
- Gogna A, Pradhan GR, Sinha RS, Gupta B. Tuberculosis presenting as deep vein thrombosis. *Postgrad Med J*. 1999;75(880):104-5.
- Kumar V, Gupta KB, Aggarwal R. Deep vein thrombosis in tuberculosis. *J Infect Dis Antimicrob Agents*. 2011;28:63-7.
- Naithani R, Agrawal N, Choudhary VP. Deep venous thrombosis associated with tuberculosis. *Blood Coagul Fibrinolysis*. 2007;18(4):377-80.
- Sharma RR, Acharya KV, Poornima V. A rare complication of pulmonary tuberculosis. *J Indian Acad. Clin. Med*. 2007;8(2):179-181.
- Shah PA, Yaseen Y, Malik AH. Pulmonary Tuberculosis with Deep Venous Thrombosis. *WebmedCentral GENERAL MEDICINE* 2011;2(8):WMC002093.
- Mohan B, Kashyap A, Whig J, Mahajan V. Pulmonary embolism in cases of pulmonary tuberculosis: a unique entity. *Indian J Tuberc*. 2011;58(2):84-7.
- Sangani J, Mukherjee S, Biswas S, Chaudhuri T, Ghosh G. Tuberculosis and acute deep vein thrombosis in a pediatric case. *Journal of Clinical and Diagnostic Research: JCDR*. 2015;9(6):SD01.
- Muley P, Shah U, Shah V, Gandhi D. Deep vein thrombosis with tuberculosis: A rare presentation of common disease. *Global J Med Public Health*. 2014;3(1).

---

**Acknowledgments**

None.

**Conflict of Interest Statement & Funding**

The Authors have no funding, financial relationships or conflicts of interest to disclose.

**Author Contributions**

Conceptualization: VM, GB. Methodology: VM, GB, RC, AS. Software: VM, RC, AS. Validation VM, GB, RC, AS. Formal Analysis: VM, GB, RC, AS. Writing Review and Editing VM, GB, RC, AS. Writing –Original Draft RC, AS. Data Curation: GB, RC, AS. Investigation: GB, RC, AS.

**Cite as**

Marwah V, Bhati G, Choudhary R, Sharma A. Pulmonary Thromboembolism in Multidrug-Resistant Tuberculosis: A Case Series Highlighting the Importance of Early Diagnosis and Management. Int J Med Stud. 2023 Oct-Dec;11(4):321-25.

*This work is licensed under a [Creative Commons Attribution 4.0 International License](#)*

ISSN 2076-6327

This journal is published by [Pitt Open Library Publishing](#)

**Pitt** Open  
Library  
Publishing