

# Histopathologic Insights and Treatment Outcomes in PD-1 and PDL-1 Cutaneous Immune-Related Adverse Events: A Case Series

Amanda Rodriguez Orengo,<sup>1</sup> Alicia Mizes,<sup>2</sup> Irina Lerman,<sup>3</sup> Abigail I. Franco,<sup>2</sup> Mary Gail Mercurio,<sup>2</sup> Paul Blackcloud.<sup>2</sup>

## Abstract

**Background:** Immune checkpoint inhibitors (ICIs), including therapies targeting anti-programmed cell death protein 1 (PD-1) or anti-programmed death-ligand 1 (PDL-1), are highly effective for treating various malignancies, but are often associated with immune-related adverse events (irAEs). Among these, cutaneous irAEs are the most prevalent, affecting about half of patients and varying widely in severity. irAEs can impact quality of life and lead to treatment discontinuation. Managing these side effects effectively is essential to allow continuation of therapy without compromising its efficacy. **Methods:** Retrospective case series. **Results:** We present three patients who developed severe cutaneous irAEs: two with pembrolizumab-induced lichenoid dermatitis and one with atezolizumab-induced psoriasiform rash. Initial treatment was guided by histopathologic findings, leading to the use of dupilumab, an interleukin-4 receptor (IL-4Ra) monoclonal antibody, in all three cases. While two patients achieved full resolution with dupilumab, the third case, which progressed to a clinically psoriasiform morphology, was later treated with apremilast, a phosphodiesterase 4 (PDE4) inhibitor, resulting in significant improvement. **Conclusion:** These cases highlight the critical role of combining histopathologic and clinical insights to customize treatment approaches. Both dupilumab and apremilast are steroid-sparing options with favorable safety profiles and offer effective alternatives to systemic corticosteroids without compromising the efficacy of ICIs.

## Introduction

Immune checkpoint inhibitors (ICI) that target anti-programmed cell death protein 1 (PD-1) or anti-programmed death-ligand 1 (PDL-1) are utilized in the management of many malignancies, including melanoma, lung and renal cancer. They enhance antitumoral activity by reducing T cell inhibition; however, immune system activation is not specific to the tumor microenvironment, resulting in immune related adverse events (irAE).

Cutaneous irAE occur in up to 30-60% of patients taking ICIs and can have a wide variety of clinical presentations.<sup>1</sup> Common clinical manifestations include maculopapular, eczematous, psoriasiform, and lichenoid rashes. Pruritus may also present either alone or in association with a rash.<sup>2</sup>

Understanding the histopathologic and clinical features of cutaneous irAEs is important to determine the most appropriate treatment plan. We describe the cases of three patients, with a focus on histopathologic findings, who developed cutaneous irAEs secondary to either PD-1 (pembrolizumab) or PDL-1 (atezolizumab) inhibitors and were successfully treated with either dupilumab or apremilast.

## Methods

This study was designed as a retrospective case series conducted at the Department of Dermatology at the University of Rochester

Medical Center. Medical records were reviewed to identify patients who developed cutaneous immune-related adverse events (irAEs) associated with immune checkpoint inhibitors targeting PD-1 or PD-L1. Inclusion was limited to patients who received treatment with steroid-sparing agents, specifically dupilumab or apremilast, for management of their dermatologic toxicity.

Clinical data were extracted from electronic health records, including patient demographics, cancer diagnosis, type and duration of immune checkpoint inhibitor therapy, timing and severity of cutaneous irAEs, and prior treatments. Severity was classified according to the Common Terminology Criteria for Adverse Events (CTCAE). Histopathologic evaluation was performed through skin biopsies, which were reviewed to characterize inflammatory patterns and guide treatment decisions.

Treatment regimens, including dosing and duration of dupilumab and apremilast, were documented. Outcomes assessed included clinical response (based on body surface area involvement and symptom resolution), need for modification or discontinuation of oncologic therapy, and adverse effects related to treatment. Follow-up data were collected to evaluate durability of response and oncologic outcomes when available.

<sup>1</sup> Fourth-year Medical Student, BS. University of Rochester School of Medicine, Rochester, NY, United States of America.

<sup>2</sup> MD. Department of Dermatology, University of Rochester Medical Center, Rochester, NY, United States of America.

<sup>3</sup> MD, PhD. Department of Dermatology, University of Rochester Medical Center, Rochester, NY, United States of America.

**About the Author:** Amanda Rodriguez Orengo is currently a fourth-year medical student at the University of Rochester School of Medicine, Rochester, NY, USA, a four-year program. She is also a recipient of a Levitan student fellowship grant.

### Correspondence:

Alicia Mizes.

Address: 40 Celebration Drive, Rochester, NY 14620

Email: [alicia\\_mizes@urmc.rochester.edu](mailto:alicia_mizes@urmc.rochester.edu)

Editor: Francisco J. Bonilla-Escobar  
Student Editors: Rahul Kumar Chaudhary,  
Priscilla Lilechi, Priyanka Nayak &  
Radu Marinescu

Submission: Jun 19, 2025  
Revisions: Dec 1, 2025  
Responses: Feb 26, 2026  
Acceptance: Mar 16, 2026  
Publication: Mar 16, 2026  
Process: Peer-reviewed

All patients provided written informed consent for the use of their clinical data and images for publication.

## Results

**Table 1** provides a comprehensive summary of the primary characteristics of three patients seen at the University of Rochester Dermatology Department for management of their irAEs, including clinical and histopathologic features, treatment regimens, and cancer outcomes.

### Case 1

An 87-year-old woman with stage IV lung squamous cell carcinoma receiving palliative pembrolizumab developed a diffuse pruritic rash starting six months after initiating therapy. Physical exam was notable for pink scaly papules coalescing into large plaques with overlying hemorrhagic crust involving >60% of her body surface area (BSA), including the extremities and trunk, but sparing the hands, feet, and face.

Her symptoms and rash had only minimal improvement with triamcinolone 0.1% cream twice daily, pramoxine hydrochloride lotion as needed, and fexofenadine 180 mg twice daily. Pembrolizumab was held, and she started a 1mg/kg prednisone taper. The taper was started at 50 mg and was intended to decrease by 10 mg weekly. It was extended over four months due to poor symptom control below 30 mg prednisone.

Five months after the rash onset, she was seen by dermatology and punch biopsies taken from her arm and thigh showed a band-like infiltrate of lymphocytes and rare eosinophils

suggestive of lichenoid dermatitis (**Figure 1B**). Given the severity of her pruritus and failure to improve with prednisone, dupilumab (600mg loading dose and 300mg every other week) was initiated.

Two months later, she was hospitalized for failure to thrive, and dermatology was consulted due to worsening of her rash (**Figure 1A**). A repeat punch biopsy was performed, which showed ulcer bed, not indicative of a new etiology.

Three and a half months after dupilumab initiation, her rash and pruritus were both improving and completely resolved (i.e. BSA 0%) after an additional two months. At her last follow up with dermatology, 6 months after the rash resolved, she did not report any rash recurrence or side effects of treatment.

After a goals of care discussion with oncology, the decision was made not to resume pembrolizumab. Despite not resuming treatment, she had had no signs of disease progression on CT chest and abdomen and continued to receive frequent monitoring via imaging.

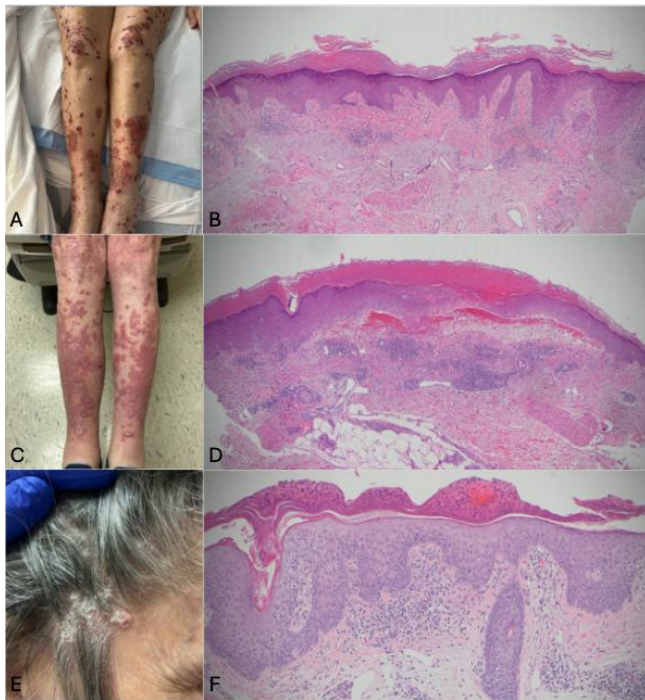
### Case 2

A 71-year-old woman with stage IIC cutaneous melanoma, classified as high risk for micro-metastatic disease (DecisionDx class IIB), began treatment with adjuvant pembrolizumab, for a planned duration of one year. After one dose, she developed ill-defined, pink annular patches on the bilateral axillae and upper lateral trunk. These did not progress until three months into treatment, when she developed more extensive erythematous, pink papules on the chest, upper back and upper extremities covering >10% BSA.

**Table 1: Patient Case Characteristics, Immune Related Adverse Event Type, Histology and Treatment**

Pt.	Sex	Cancer Type	ICI Treatment	Cutaneous irAE	CTCAE Grade	irAE Histopathology	Dupilumab or Apremilast Dosing	Cancer Outcomes
1	F	Stage V squamous cell carcinoma of the lung	Palliative pembrolizumab (PD-1)	Lichenoid dermatitis	3	Mild orthokeratotic hyperkeratosis and focal parakeratosis, wedge-shaped hypergranulosis of the acanthotic epidermis, a saw-tooth-like change to the rete ridge pattern, abundant dying keratinocytes, a dense band-like infiltrate of lymphocytes that focally obscures the dermal epidermal junction and rare eosinophils, consistent with dermatitis	Dupilumab 600mg loading dose followed by 300mg every other week	No evidence of disease progression
2	F	Stage IIC cutaneous melanoma	Adjuvant pembrolizumab (PD-1)	Lichenoid dermatitis	3	Extensive apoptotic basal layer keratinocytes leading to subepidermal blistering, epidermal hyperkeratosis and hypergranulosis within the dermis, a superficial lymphocytic perivascular infiltrate and focal mild lymphocytic vacuolar interface dermatitis, consistent with lichenoid dermatitis	Dupilumab 600mg loading dose followed by 300mg every other week	No evidence of disease recurrence
3	F	Extensive stage small cell lung cancer	Palliative atezolizumab (PDL-1)	Mixed eczematous and psoriasiform presentation	3	Mild irregular acanthosis of the epidermis with diffuse spongiosis, overlying parakeratotic scale with entrapped serum and accentuation of parakeratin around hair follicles and edema, lymphocytes and eosinophils in the papillary dermis, suggestive of seborrheic dermatitis or a spongiform drug eruption	Dupilumab 600mg loading dose followed by 300mg every other week transitioned to Apremilast 30mg twice daily	Lung mass stable, new brain metastasis on imaging

**Legend:** ICI, immune checkpoint inhibitor, irAE, immune-related adverse events; CTCAE, Common Terminology Criteria for Adverse Events.

**Figure 1. Clinical and Histopathology Images for Each Case Described.**

**Legend:** Case 1. A, Clinical image of the bilateral lower legs during inpatient hospital stay. B, Histology (H&E) at 40x showing mild orthokeratotic hyperkeratosis and focal parakeratosis, wedge-shaped hypergranulosis of the acanthotic epidermis, a saw-tooth-like change to the rete ridge pattern, abundant dying keratinocytes, a dense band-like infiltrate of lymphocytes that focally obscures the dermal epidermal junction and rare eosinophils, consistent with lichenoid dermatitis. Case 2. C, Clinical image of the lower extremities around the time of dupilumab initiation. D, Histology (H&E) at 40x showing extensive apoptotic basal layer keratinocytes, epidermal hyperkeratosis and hypergranulosis within the dermis, a superficial lymphocytic perivascular infiltrate and focal mild lymphocytic vacuolar interface dermatitis, consistent with lichenoid dermatitis. Case 3. E, Clinical image of the scalp prior to apremilast initiation. F, Histology at 100x showing mild irregular acanthosis of the epidermis with diffuse spongiosis, overlying parakeratotic scale with entrapped serum and accentuation of parakeratin around hair follicles, and edema, lymphocytes.

She started triamcinolone 0.1% cream twice daily, but after another four months, she experienced severe pruritus and the rash spread to her trunk and lower extremities, leading to pembrolizumab discontinuation. She had only minimal improvement with clobetasol 0.05% ointment twice daily, fexofenadine 180 mg daily, hydroxyzine 10 mg three times daily and famotidine 20 mg twice daily.

A punch biopsy of the thigh showed a lymphocytic vacuolar interface infiltrate suggestive of lichenoid dermatitis with secondary subepidermal blistering due to extensive apoptosis ([Figure 1D](#)). Her symptoms continued to be refractory to a 15-day prednisone taper, starting at 40mg daily and decreasing by 10 every 5 days.

Due to poor corticosteroid response ([Figure 1C](#)), dupilumab (600mg loading, then 300mg biweekly) was started. After one dose, she noted some improvement, and after five months, her

rash had fully resolved (i.e. BSA 0%). She remained completely clear at follow-up 14 months after rash resolution, and dupilumab was discontinued.

Since pembrolizumab was given as adjuvant therapy and there was no evidence of recurrence on imaging, rechallenge was not pursued. No dupilumab side effects were reported throughout her treatment course. Although she never restarted pembrolizumab after her initial seven months of treatment, she remained free of melanoma recurrence on imaging, ctDNA surveillance and exam.

### Case 3

A 72-year-old woman with extensive small cell lung cancer (E-SCLC) metastatic to the brain, and a history of indolent B-cell non-Hodgkin's lymphoma and urothelial carcinoma was receiving palliative atezolizumab 1200 mg every three weeks for her E-SCLC. 18 months into treatment, she developed a pruritic rash consisting of a few pink papules and greasy scale isolated to the scalp. She initially started over the counter hydrocortisone 1% cream twice daily and ketoconazole 1% shampoo daily with adequate symptom control.

Two months later, she developed worsening pruritus and similar psoriasiform salmon-colored papules and plaques with silvery scale on the neck, chest, back, abdomen and bilateral extremities, covering >30% BSA. She was referred to dermatology and a shave biopsy of the temple showed subacute spongiotic dermatitis with shoulder parakeratosis and follicular plugging, suggestive of seborrheic dermatitis or a spongiform drug eruption ([Figure 1E](#)). A deep shave biopsy was selected because it allowed for more extensive sampling, including the dermis, while also permitting healing by secondary intention in the temple region, which typically heals well using this approach.

Two months later, the rash had not improved with fluocinonide 0.05% solution twice daily, tacrolimus 0.1% ointment twice daily, triamcinolone 0.1% cream twice daily, and cetirizine 10mg daily. Due to poor response to topical treatments, dupilumab was started (600 mg loading, then 300 mg biweekly), but after three doses, her rash and pruritus persisted, even with the addition of clobetasol 0.05% cream and solution twice daily.

Given the psoriasiform appearance of the rash ([Figure 1E](#)) and the safety of apremilast while receiving immunotherapy, apremilast was initiated and tapered up to 30 mg twice daily. One month later, her rash and pruritus had significantly improved, and she stopped dupilumab, but continued to take apremilast. Due to rapid improvement of the rash with apremilast, a repeat biopsy was considered unnecessary due to not changing management.

She continued atezolizumab during this time due to cancer progression and metastases. Her lung cancer remained stable on chest CT, but a new brain metastasis was found on MRI, for which she received stereotactic radiosurgery. She continued to take

apremilast, with even greater improvement of her rash three months after starting the medication. At 14 months after starting apremilast, her rash remained stable, although complete clearance was not achieved. BSA was reported as <10%, improved from >20% BSA. She did not report any side effects from apremilast.

## Discussion

ICIs are effective against numerous malignancies, but they cause non-specific immune system activation, leading to irAEs. They can affect multiple organ systems, but cutaneous irAEs are the most common and often develop the earliest.<sup>3</sup> Some evidence suggests that irAEs, including cutaneous manifestations such as lichenoid eruptions, psoriasiform eruptions, pruritus, and acneiform eruptions, as well as non-cutaneous irAEs, are associated with improved survival among ICI recipients, regardless of hospitalization for these events.<sup>4,5</sup> In most cases, irAEs are mild to moderate, but approximately 20% are severe, resulting in disruption of activities of daily living and ICI discontinuation.<sup>6</sup>

Current consensus guidelines for cutaneous irAEs are based on the Common Terminology Criteria for Adverse Events (CTCAE) which grades irAEs based on severity.<sup>3,6,7</sup> Treatment guidelines differ depending on the clinical and histopathologic appearance of the eruption, but for most types of reactions, treatment relies heavily on systemic corticosteroids and other immunosuppressive agents.<sup>6</sup> Conflicting evidence exists on whether steroids and other second-line immunosuppressive agents, due to diminished ICI efficacy or alterations to the tumor microenvironment, influence cancer progression in patients on ICIs.<sup>1</sup> Biologics are used only for severe (grade 3+) reactions.

For lichenoid dermatitis, guidelines recommend using infliximab or tocilizumab.<sup>6</sup> However, recently reported cases suggest that dupilumab, a monoclonal antibody targeting the interleukin-4 receptor (IL-4Ra), can be used for the treatment of lichenoid dermatitis secondary to ICI use.<sup>8,9</sup> IL-13 expression in two patient biopsies suggests a role for type 2 inflammation in ICI-induced lichenoid dermatitis and provides rationale for treatment with IL-4R $\alpha$  antagonism.<sup>8</sup> Since dupilumab is not an immunosuppressant, it may be a safer alternative to systemic corticosteroids and other immunosuppressants in regard to side effects and the influence on antitumor response. Dupilumab has been successful for the treatment of many skin irAEs inflammatory patterns including spongiotic dermatitis, interface dermatitis, lichenoid dermatitis, perivascular dermatitis and sparse perivascular infiltrate, with an 87% overall treatment response rate. For severe psoriasiform rash induced by ICIs, biologics used for treatment include ustekinumab, guselkumab, infliximab, adalimumab.<sup>6</sup> Apremilast, an oral small molecule phosphodiesterase 4 (PDE4) inhibitor, has also been used to treat cutaneous irAEs with psoriasiform morphology. In a study of 5 patients treated with apremilast for de-novo ICI induced psoriasis, 80% had a partial response or improvement, while in a case series of three patients, all showed

clinical improvement in PASI and BSA.<sup>10,11</sup> PDE4 inhibition elevates intracellular cAMP, promoting anti-inflammatory cytokine production (e.g., IL-10) and suppressing proinflammatory cytokines such as IL-17, IL-22, and IL-13.<sup>10</sup> Like dupilumab, apremilast is also regarded as an immunomodulating agent instead of an immunosuppressant drug and is thought to have a better safety profile in patients receiving ICIs.

Our case series highlights two instances where dupilumab was successfully used to treat pembrolizumab-induced lichenoid dermatitis, both demonstrating classic histopathologic findings of lichenoid dermatitis.<sup>12</sup> Additionally, we report a case in which biopsy findings revealed subacute spongiotic dermatitis, prompting treatment with dupilumab, with no improvement. Based on the rash's clinical presentation, which appeared more psoriasiform especially as it progressed, apremilast was initiated and resulted in substantial improvement in pruritus and reduction to <10% BSA. Literature suggests that about 15% of irAEs with a spongiotic dermatitis inflammatory pattern do not respond to dupilumab, which may explain treatment failure in this case.<sup>9</sup> Furthermore, at the time of biopsy for the third case, the rash had not yet evolved to a psoriasiform appearance, raising the possibility that a repeat biopsy might have revealed different histopathologic findings. We suggest that the consideration of a particular therapy for treating irAEs should be based on the combination of the histopathologic findings and the clinical appearance and progression of the rash. Another factor to consider is that in the first two cases, pembrolizumab treatment was discontinued, whereas in the third case, atezolizumab was continued, potentially contributing to the lack of improvement with dupilumab.

Our case series underscores the importance of utilizing both histopathologic and clinical findings in guiding treatment decisions, particularly for immunomodulating drugs, such as dupilumab and apremilast. We believe that both dupilumab and apremilast agents are excellent steroid-sparing agents to consider instead of other more potentially immunosuppressive biologics for treating irAEs. The evolving clinical and histopathologic presentations of irAEs highlight the need for a dynamic approach to diagnosis and management, tailored to the unique characteristics of each case.

## Limitations

Our case series included all patients identified by the authors who were treated with dupilumab or apremilast for cutaneous irAEs (n=3). No additional cases, including non-responders, were identified. We acknowledge that larger cohorts or comparative studies with standard therapies would strengthen these conclusions. Additionally, patient perspectives on treatment were not included, as these data were not collected during treatment or follow-up. Finally, discontinuation of pembrolizumab in Cases 1 and 2 while atezolizumab was continued in Case 3 may have influenced treatment response, potentially leading to resolution with dupilumab in the first two cases and lack of improvement in the third.

## References

1. Quach HT, Johnson DB, LeBoeuf NR, Zwerner JP, Dewan AK. Cutaneous adverse events caused by immune checkpoint inhibitors. *J Am Acad Dermatol* 2021;85(4):956-966.
2. Apalla Z, Papageorgiou C, Lallas A, Delli F, Fotiadou C, Kemanetzi C, et al. Cutaneous Adverse Events of Immune Checkpoint Inhibitors: A Literature Review. *Dermatol Pract Concept* 2021;11(1):e2021155.
3. Phillips GS, Wu J, Hellmann MD, Postow MA, Rizvi NA, Freites-Martinez A, et al. Treatment Outcomes of Immune-Related Cutaneous Adverse Events. *J Clin Oncol* 2019;37(30):2746-2758.
4. Cook S, Samuel V, Meyers DE, Stukalin I, Litt I, Sangha R, et al. Immune-Related Adverse Events and Survival Among Patients with Metastatic NSCLC Treated with Immune Checkpoint Inhibitors. *JAMA Netw Open* 2024;7(1):e2352302.
5. Zhang S, Tang K, Wan G, Nguyen N, Lu C, Ugwu-Dike P, et al. Cutaneous immune-related adverse events are associated with longer overall survival in advanced cancer patients on immune checkpoint inhibitors: A multi-institutional cohort study. *J Am Acad Dermatol* 2023;88(5):1024.
6. Geisler AN, Phillips GS, Barrios DM, Wu J, Leung DYM, Moy AP, et al. Immune checkpoint inhibitor—related dermatologic adverse events. *J Am Acad Dermatol* 2020;83(5):1255.
7. Sibaud V, Meyer N, Lamant L, Vigarios E, Mazieres J, Pierre Delord J. Dermatologic complications of anti-PD-1/PD-L1 immune checkpoint antibodies. *Curr Opin Oncol* 2016;28(4):254-263.
8. Park JJ, Park E, Damsky WE, Vesely MD. Pembrolizumab-induced lichenoid dermatitis treated with dupilumab. *JAAD Case Reports* 2023;37:13.
9. Kuo AM-S, Gu S, Stoll J, Moy AP, Dusza SW, Gordon A, et al. Management of immune-related cutaneous adverse events with dupilumab. *J Immunother Cancer* 2023;11(6):e007324.
10. Mayor Ibarguren A, Enrique EA, Diana PL, Ana C, Pedro HP. Apremilast for immune checkpoint inhibitor-induced psoriasis: A case series. *JAAD Case Rep* 2021;11:84-89.
11. Ghosh N, Reid P, Sparks JA, McCarter K, Ge K, Bass AR. Use of Apremilast for the Treatment of Immune Checkpoint Inhibitor-Induced Psoriasis and Psoriatic Arthritis. *Arthritis Care Res (Hoboken)* 2025;77(12):1487-1492.
12. Ellis S, Vierra AT, Millsop JW, Lacouture ME, Kiuru M. Dermatologic toxicities to immune checkpoint inhibitor therapy: A review of histopathologic features. *J Am Acad Dermatol* 2020;83(4):1130.

## Acknowledgments

None.

## Conflict of Interest Statement & Funding

The Authors have no funding, financial relationships or conflicts of interest to disclose.

## Author Contributions

Conceptualization: ARO, AM, IL. Supervision: IL, AF, MGM, PB. Writing - Original Draft: ARO. Writing - Review Editing: AM, IL, AF, MGM, PB.

## Cite as

Rodriguez Orengo A, Mizes A, Lerman I, Franco AI, Mercurio MG, Blackcloud P. Histopathologic Insights and Treatment Outcomes in PD-1 and PD-L1 Cutaneous Immune-Related Adverse Events: A Case Series. *Int J Med Stud*. 2022 Jan-Mar;14(1):19-23.

*This work is licensed under a [Creative Commons Attribution 4.0 International License](https://creativecommons.org/licenses/by/4.0/)*

ISSN 2076-6327

This journal is published by [Pitt Open Library Publishing](https://open.library.pitt.edu/)

