

CASE STUDY**112. When Bone Forms in the Endometrium: A Case of Osseous Metaplasia Presenting with Chronic Pelvic Pain and Abnormal Uterine Bleeding**

Wilson Sebastian Peñafiel-Pallares,¹ Camila Brito-Balanzategui,¹ Oscar Venegas-Baca.²

¹ Universidad de las Americas, Ecuador

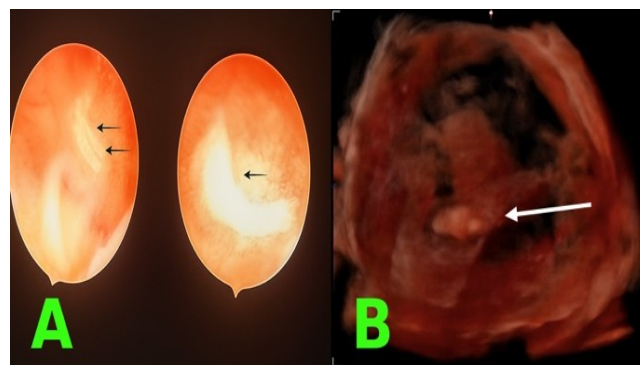
² Hospital de Nueva Aurora-Luz Elena Arismendi, Ecuador

Background: Endometrial osseous metaplasia is a rare condition characterized by the transformation of endometrial stromal cells into osteoblast-like cells. Its etiology remains uncertain, but proposed risk factors include a history of abortion and chronic intrauterine inflammation. This condition is clinically relevant because it can cause infertility, abnormal uterine bleeding, and pelvic pain, particularly in young women. Early recognition and management are crucial to avoid long-term sequelae.

Case: A 20-year-old woman with past medical history of spontaneous abortion six months ago, presented with pelvic pain and abnormal uterine bleeding. Transvaginal ultrasonography revealed echogenic structures suggestive of intrauterine calcifications. Hysteroscopy confirmed the presence of osseous tissue within the endometrial cavity, which was completely resected. Histopathology confirmed the diagnosis of endometrial osseous metaplasia. The postoperative course was uneventful, and symptoms resolved following treatment.

Conclusion: Endometrial osseous metaplasia, though rare, should be considered in young women with recent abortions presenting with abnormal uterine bleeding, pelvic pain, or infertility. Ultrasonography serves as a valuable initial diagnostic tool, while hysteroscopy remains the gold standard for both diagnosis and treatment. This case highlights the importance of clinical awareness to ensure timely recognition and management of this uncommon entity.

Figure:1. Hysteroscopy and Three-Dimensional Reconstruction Demonstrating Foreign Material Within the Endometrial Cavity.



Legend: Endometrial osseous metaplasia in hysteroscopy and transvaginal ultrasound. (A) Black arrows showing small, white, irregular foreign bodies, found on endometrial cavity during hysteroscopy. (B) Three-dimensional reconstruction of the uterine cavity showing irregular echogenic areas corresponding to osseous fragments (white arrow).

This work is licensed under a [Creative Commons Attribution 4.0 International License](#)

ISSN 2076-6327

This journal is published by [Pitt Open Library Publishing](#)

Pitt Open
Library
Publishing