


44. Leishmaniasis in a Patient with Congenital Neutropenia - A Rare Case Report

Karima Boughambouz¹, Sana Bouimout¹, Yasmine Bouferkas¹, Myriam Boueri²

¹ Medical student, The Faculty of Medicine, University of Algiers I Benyoucef Benkhedda, Algiers, Algeria

² MD, Faculty of Medicine, Lebanese American University, Beirut, Lebanon

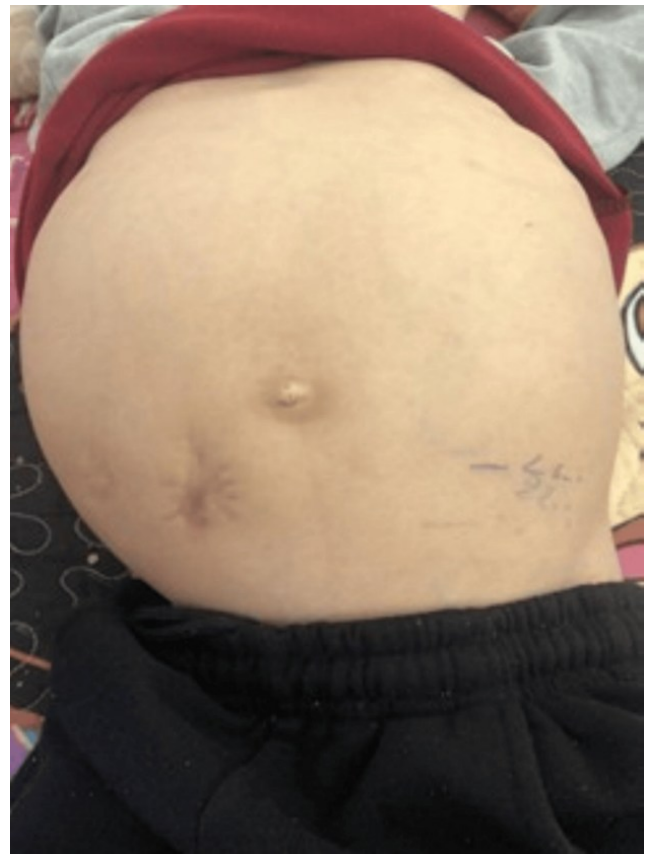 <https://www.youtube.com/watch?v=4rJ3DHWeKR&list=PLhqNq3xJClbafO0Y5bvBcgMmXpgzJxd44&index=6&t=14150s>

Background: Visceral leishmaniasis is a parasitic disease caused by *Leishmania* species and transmitted by sandflies. It typically presents with fever, hepatosplenomegaly, and cytopenias. Congenital neutropenia is a rare primary immunodeficiency characterized by recurrent infections due to persistently low neutrophil counts. To our knowledge, the coexistence of congenital neutropenia and visceral leishmaniasis has not previously been reported.

The Case: We describe an eight-year-old child with congenital neutropenia who presented with pallor and hepatosplenomegaly, notably in the absence of fever. Laboratory studies showed pancytopenia with severe neutropenia. Given this constellation of findings, several differential diagnoses were initially considered, with leukemia being strongly suspected. Bone marrow aspiration was performed to confirm the diagnosis. Unexpectedly, the marrow examination revealed numerous *Leishmania* amastigotes, establishing the diagnosis of visceral leishmaniasis. The patient was treated with liposomal amphotericin B, resulting in a gradual clinical recovery and normalization of counts.

Conclusion: This report represents the first documented case of concurrent congenital neutropenia and visceral leishmaniasis. It highlights the importance of maintaining a broad differential diagnosis in immunocompromised patients presenting with cytopenias and organomegaly, even in the absence of fever. Early recognition of visceral leishmaniasis remains critical, as timely treatment can substantially improve outcomes.

Figure 1. Clinical photograph showing the patient's abdomen after treatment.



This work is licensed under a [Creative Commons Attribution 4.0 International License](#)

ISSN 2076-6327

This journal is published by [Pitt Open Library Publishing](#)

Pitt Open Library Publishing