

## CASE STUDY

107. **Giant Left Diaphragmatic Hernia Complicated With Intrathoracic Gastric Volvulus and Total Gastric Necrosis: An Uncommon Case Report**

Sofia Rubiralta Adame<sup>1</sup>, Martin Rodriguez Alvarado<sup>2</sup>,  
Mariana Fraga Duarte<sup>3</sup>, Jack Abadi Chiriti<sup>4</sup>, Jair Ariel Nava  
Vazquez<sup>2</sup>, Emanuel Osmar Diaz Vega<sup>2</sup>

<sup>1</sup> Panamerican University School of Medicine, Mexico

<sup>2</sup> National Polytechnic Institute, Mexico

<sup>3</sup> La Salle University School of Medicine, Mexico

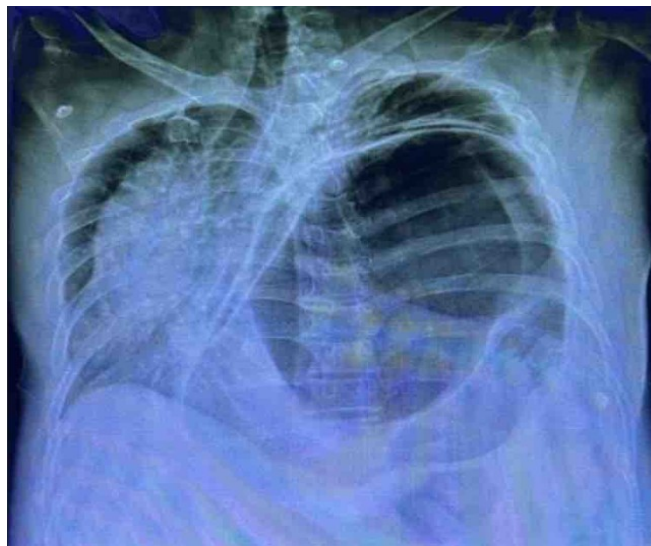
<sup>4</sup> The American British Cowdray Medical Center, Mexico

**Background:** Diaphragmatic hernia in adults is an uncommon but potentially fatal condition. Diagnosis is often delayed because of nonspecific symptoms, predisposing patients to severe complications. Among these, intrathoracic gastric volvulus with necrosis is one of the most catastrophic, carrying a high risk of septic shock, multiorgan failure, and postoperative mortality exceeding 30–50% in critical settings. This case is notable for the size of the hernia, the extent of gastric necrosis, and the complexity of reconstruction required, while also underscoring the need for access to specialized critical care.

**The Case:** A 66-year-old male with cirrhosis, hypertension, and diabetes presented in extremis with severe abdominal pain, distension, and acute dyspnea progressing to refractory shock. He required mechanical ventilation and vasopressor support. Examination revealed abdominal distension, tracheal deviation, and absent left breath sounds. Chest radiography showed a massively distended stomach in the left hemithorax, with mediastinal shift and contralateral lung collapse. Emergency laparotomy demonstrated a 10 × 5 cm diaphragmatic defect containing a volvulated stomach with complete necrosis. Procedures included adhesiolysis, hernia reduction, diaphragmatic repair, total gastrectomy, and Roux-en-Y reconstruction with esophagojejunal and jejunojunal anastomoses. A left chest tube and drains were placed. The surgery lasted nine hours with blood loss of 1500 mL. Postoperatively, the patient remained critically ill with hypovolemic and septic shock requiring dual vasopressors and ventilatory support.

**Conclusion:** Giant diaphragmatic hernia with intrathoracic gastric volvulus and total gastric necrosis is an exceptional, life-threatening condition. Successful management requires rapid diagnosis, immediate surgical intervention, multidisciplinary collaboration, and advanced critical care infrastructure.

**Figure 1.** Chest X-Ray:



**Legend:** Posteroanterior chest radiograph demonstrating a giant left diaphragmatic hernia with a markedly distended intrathoracic stomach, resulting in rightward mediastinal shift and collapse of the left lung. The findings are consistent with intrathoracic gastric volvulus and are suspicious for gastric ischemia or necrosis.

*This work is licensed under a [Creative Commons Attribution 4.0 International License](#)*

ISSN 2076-6327

This journal is published by [Pitt Open Library Publishing](#)

**Pitt** Open  
Library  
Publishing