

## CASE STUDY

95. **From Anatomy to Intervention: Coil Embolization of a Post-Cholecystectomy Hepatic Artery Pseudo aneurysm: A Case Report and Anatomical Insights for Medical Student**

Shahan Ahmed <sup>1</sup>, Faizan Ahmed <sup>2</sup>, Ehsan Masud Kiani <sup>3</sup>, Mahnoor Ahmed <sup>4</sup>, Anis Ahmed <sup>4</sup>, Syeda Qumreen Ahmad<sup>4</sup>, Fatima Nazir <sup>4</sup>, Kamil Ahmad Kamil

<sup>1</sup> Rawal Institute of Health Sciences, Islamabad

<sup>2</sup> Punjab Medical College, Faisalabad

<sup>3</sup> Riphah International University, Islamabad

<sup>4</sup> Rawalpindi Medical University, Rawalpindi

<sup>5</sup> Internal Medicine Department, Mirwais Regional Hospital, Kandahar, Afghanistan

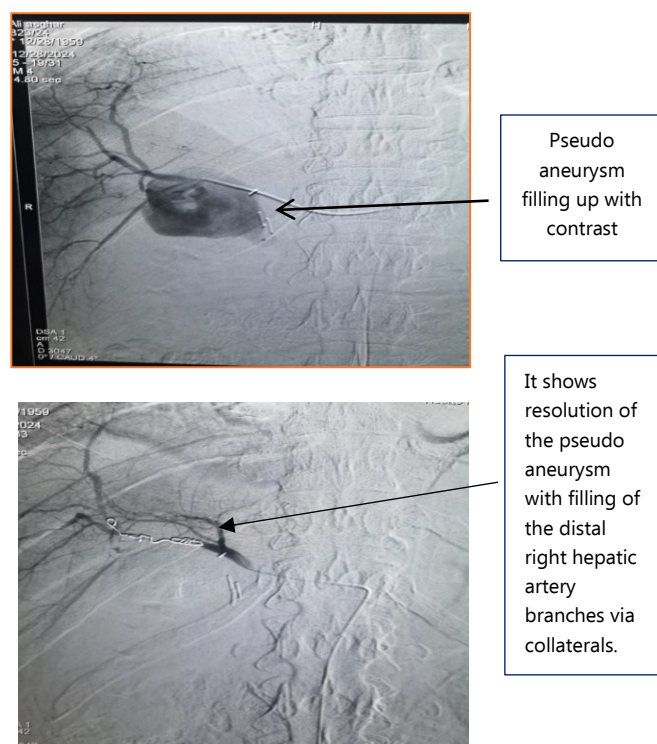
**Background:** Post-cholecystectomy vascular complications are rare, but serious. The surgical anatomy of the hepatic arteries is notoriously variable and increases the potential risk of injury during hepatobiliary surgery. Normally the hepatic artery proper bifurcates into right and left hepatic arteries. But, in one third of cases the aberrant right hepatic artery (aRHA) may originate from the superior mesenteric, gastroduodenal, right gastric artery or the coeliac trunk. Trauma from surgical clips or electrocautery can damage the aRHA during dissection at the Calot's triangle, with subsequent formation of pseudoaneurysm. This presents late after surgery, mostly as GI bleed, right upper quadrant pain and jaundice—the Quinke's triad. This case report presents pseudoaneurysm formation after injury to aRHA during cholecystectomy which was subsequently managed with coil embolization.

**The Case:** A 65-years-old gentleman presented with right hypochondrial pain of 5-months duration which was confirmed to be due to gallstones on ultrasonography. He was admitted for cholecystectomy. Intraoperatively, during laparoscopiccholecystectomy Calot's triangle was identified and cystic artery and duct were clipped under vision and cut. While removing the gallbladder massive bleeding was observed for which the procedure had to be converted to open cholecystectomy. Upon inspection an aberrant right hepatic artery was found which was ligated, while 02 pints of blood were transfused. After hemostatic control, bile leak was observed, for which T-tube was placed in the common bile duct. Postoperatively, there was a gradual decrease of his t-tube output. On the 10th post-operative day, patient became apprehensive and there was massive bleeding from T-tube site and in the sub hepatic drain. He developed shock, for which he was resuscitated. Over next week bleeding progressively decreased. Meanwhile, ultrasound showed no intra-abdominal collection but a hypo-echoic area at the porta hepatis. CT angiogram showed a pseudo-aneurysm of RHA and it was aberrantly arising directly from the celiac trunk. The case was discussed in multi-disciplinary meeting, and it was decided that patient needed coil embolization of the pseudo-aneurysm. Procedure was performed by interventional radiologist through right femoral access with 4 Fr C2 catheter. Wire was advanced into the distal right hepatic artery and embolization done with a long 6 mm coils. Coiling was done distal and proximal to the neck of the pseudo-aneurysm. No complications were observed. Post embolization patient remained stable with no bleeding episode. Hemoglobin and liver functions showed improving trend after the intervention. T-tube was removed after an unremarkable cholangiogram. Patient was discharged and follow-up after 2 and 4

weeks showed clinical improvement and no further episode of bleeding. Post-embolization angiogram at 2-week follow-up showed no filling of the pseudo-aneurysm with filling of the distal right hepatic artery branches via collaterals.

**Conclusion:** This case underscores the importance of knowledge of hepatobiliary vascular anatomy in clinical practice, which enables a surgeon to anticipate challenges and tailor operative strategies accordingly. When an unexplained hemorrhage occurs in the post-cholecystectomy period, CT angiography should be used promptly to detect the cause including pseudo-aneurysm of aRHA and endovascular coil embolization is an effective and minimally invasive intervention with good results.

**Figure 1.** CT Angiogram; Pre and Post-embolization



*This work is licensed under a [Creative Commons Attribution 4.0 International License](https://creativecommons.org/licenses/by/4.0/)*

ISSN 2076-6327

This journal is published by [Pitt Open Library Publishing](https://pittopenlibrarypublishing.com/)

**Pitt** Open Library Publishing