

CASE STUDY**111. Atypical Presentation of a Hypopharyngeal Leiomyoma:****Case Report**

Jair Ariel Nava Vazquez¹, Martin Rodriguez Alvarado¹,
Alessandro Nava Torres², David Rui-Jing Guo³, Neil Parikh⁴,
Ramon Adrian Magaña Davalos⁵

¹ Instituto Politécnico Nacional, Ciudad de México, México.

² Universidad Autónoma de Guadalajara, Mexico

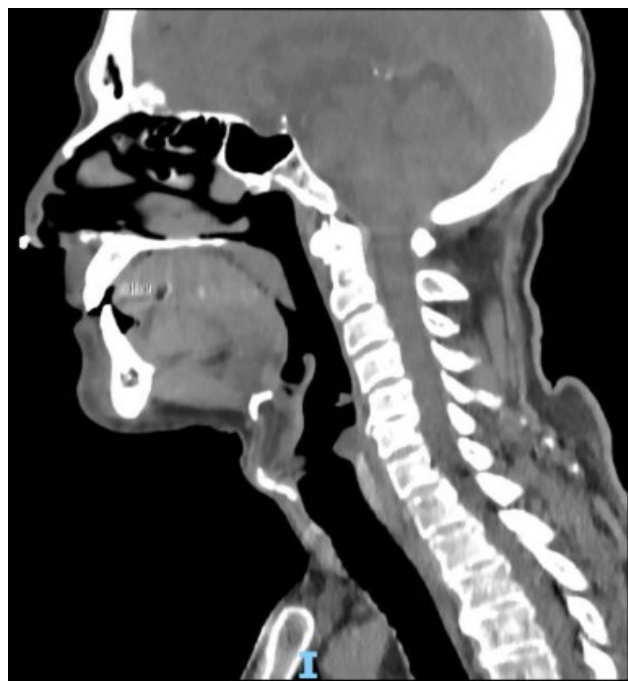
³ New York University, NY, USA

⁴ University of Virginia, VA, USA

⁵ Universidad de Monterrey, Mexico

Leiomyomas are benign tumors of smooth muscle origin, most frequently located in the uterus and gastrointestinal tract. Their presence in the hypopharynx is extremely rare due to the limited amount of smooth muscle in this region, and clinical manifestations are often nonspecific, including dysphagia, globus sensation, and pharyngeal discomfort, which may mimic malignant disease. We report the case of a 63-year-old male with a history of gastroesophageal reflux disease (GERD) and Barrett's esophagus who presented with a one-year history of dyspepsia, globus sensation, and progressive dysphagia. Endoscopic evaluation revealed a small lesion on the posterior hypopharyngeal wall, further confirmed by contrast-enhanced computed tomography as a 7 × 6 × 4 mm homogeneous, hypervascular, pedunculated mass without cervical lymphadenopathy. The patient underwent endoscopic cold-cut resection, which led to complete symptom resolution. Histopathological analysis demonstrated a well-circumscribed neoplasm composed of spindle-shaped cells arranged in fascicles, with no atypia, necrosis, or abnormal mitoses. Immunohistochemistry revealed diffuse positivity for smooth muscle actin, confirming the diagnosis of hypopharyngeal leiomyoma. The postoperative course was uneventful, with continued GERD management. This case illustrates an exceptionally rare benign tumor of the hypopharynx, emphasizing the importance of including such entities in the differential diagnosis of patients with nonspecific pharyngeal symptoms. Accurate diagnosis requires thorough endoscopic and radiological evaluation combined with histopathological confirmation. Complete surgical excision remains curative, providing excellent prognosis with minimal risk of recurrence. This report contributes to the limited literature on hypopharyngeal leiomyomas and highlights the value of a multidisciplinary approach in their management.

Figure 1. Sagittal Head CT: Nasopharynx and Cervical Spine



Legend: Computed tomography of the neck. Presence of a polypoid projection measuring 7 × 6 × 4 mm, with homogeneous enhancement after contrast administration.

This work is licensed under a [Creative Commons Attribution 4.0 International License](https://creativecommons.org/licenses/by/4.0/)

ISSN 2076-6327

This journal is published by [Pitt Open Library Publishing](https://pittopenlibrarypublishing.com/)

Pitt | Open
Library
Publishing