

8-Year-Old Child with Cerebral Palsy Treated with Pelvic Osteotomies Using 3.5 mm Blade Plate Having Subsequent Bilateral Implant Aseptic Loosening: A Case Report

Ahmed Nahian,¹ Julieanne P. Sees.²

Abstract

Background: Cerebral palsy (CP) is a central problem of the brain due to neurological insult that affects muscle posture, tone, and movement, resulting in poor motor control and dysfunctional muscle balance affecting hip joints in the growing child. Surgical treatment of hip and, if present, acetabular dysplasia addresses the femoral neck-shaft angle, appropriate muscle lengthening, and deficiency of acetabular coverage, as necessary. The surgeons perform proximal femoral osteotomies (PFOs) mostly with fixed angled blade plates (ABP) with proven success. The technique using an ABP is common and requires detailed attention to perform and to teach. **The Case:** In this case, an eight-year-old ambulatory patient with CP underwent bilateral proximal varus femoral derotational and pelvic osteotomies for the neuromuscular hip condition with a 3.5 mm Locking Cannulated Blade System (OP-LCP) by OrthoPediatrics Corp instead of the use of the conventional 4.5 mm ABP procedure, resulting in aseptic loosening. **Conclusion:** Due to the child's underdeveloped posture, the surgeon utilized the 3.5 mm instrumentation for a child-size implant, which worked sufficiently for the surgery but may not have loosened if a similar child-size blade plate system of 4.5 mm screws was implanted. While the ABP and OP-LCP systems are effective and safe for internal corrections of PFOs, the OP-LCP system may aid the residents in learning the procedure with higher confidence, fewer technical inaccuracies, and refined outcomes. Both systems are safer and viable for the treatment of neuromuscular hip conditions.

Key Words: Cerebral Palsy; Hip Dislocation; Osteotomy; Gait; Acetabuloplasty; Bone Anteversion (Source: MeSH-NLM).

Introduction

Cerebral palsy (CP) is a central problem of the brain due to neurological insult that affects muscle posture, tone, and movement, causing poor motor control and affecting the extremities, particularly the forces of the hip joint. In a review of children with the hip disease across all Centers for Disease Control and Prevention (CDC) sites, researchers found that 3.1 prevalence per 1,000 children were born with CP.¹ Children with CP are prone to develop hip dysplasia. Often confused with congenital dysplasia of the hip (CDH), children with CP-led hip dysplasia have different development pathways. Clinical diagnosis of CDH is carried with findings of a lax dislocated hip at birth, tighter displaying hip at six weeks postpartum, or an abnormal gait at 15 weeks postpartum. Common symptoms of CDH include asymmetrical or abducted legs along with a limited range of motion in squatting, walking, and crawling positions.^{2,3} In patients with CP, the hip is usually normal at birth, but the hampered motor development leads to dysplasia. Gross Motor Function Classification System (GMFCS) tracks movements like walking, sitting, and mobile device usage to deliver a lucid description of a child's updated motor function and a concept of what mobility aid a child may require, e.g., walking frames, crutches, and wheelchairs. The rate of hip displacement in children with CP has been demonstrated as a linear relationship with the child's GMFCS level.⁴

Surgical correction of hip dysplasia commonly involves addressing the femoral neck-shaft angle, appropriate muscle lengthening, and addressing acetabular coverage deficiency as necessary.^{5,6} Proximal

Highlights:

- Cerebral palsy (CP) is the most prevalent motor disability in childhood.
- Hip dysplasia, caused by CP, can be avoided by early screening, and fixed at a lower risk with procedural measures, i.e., osteotomies, on children with alarming hips.
- Though fruitful, the angled blade plate method of performing osteotomies is unnecessarily complex, while modern technology allows for more viable methods.

femoral osteotomies (PFOs) are mostly performed with fixed angled blade plates (ABP) with proven success, while instrumentation of proximal femoral locking plate systems is often sufficient. The osteotomy technique using an ABP, however, is complex to perform and to teach.⁶ In this case, we present an eight-year-old patient with CP who underwent bilateral hip varus femoral derotational and pelvic osteotomies for hip dysplasia with a 3.5 mm Locking Cannulated Blade System (OP-LCP) by OrthoPediatrics Corp. The patient's smaller size dictated usage of the 3.5 mm LCP for that manufacturer, which would be comparable to more conventional 4.5 mm ABP such as other systems manufactured; thus, the nature of a less robust implant strength likely resulted in the aseptic loosening.

¹ BS/DO (c), California Baptist University - Lake Erie College of Osteopathic Medicine, United States.

² FAAOS, FAOA, FAOAO, AI DuPont Hospital for Children, United States.

About the Author: Ahmed Nahian is currently a second-year BS/DO student at California Baptist University - Lake Erie College of Osteopathic Medicine, Erie, USA of an eight-year medical school program. He is also a recipient of the prestigious Parker B. Francis Fellowship in Pulmonary Critical Care Research administered by the University of Kansas Medical Center (KUMC) and is deeply interested in the musculoskeletal system and prosthetic science, as he wants to pursue orthopedic surgery after medical school.

Correspondence:

Ahmed Nahian

Address: 8432 Magnolia Ave, Riverside, CA 92504, United States

Email: ahmed.nahian.usa@gmail.com

Editor: Ryan T. Sless

Student Editors: Lourdes Adriana Medina-Gaona,

Sohaib Haseeb & Azher Syed

Copyeditor: Leah Komer

Proofreader: Madeleine Jemima Cox

Layout Editor: Annora Ai-Wei Kumar

Submission: Aug 21, 2020

Revisions required: Oct 21, 2020;

Jan 11, 2021; Feb 9, 2021

Received in revised form: Nov 19, 2020;

Jan 13, 2021; Feb 10, 2021

Acceptance: Apr 9, 2021

Publication: Apr 20, 2021

Process: Peer-reviewed

The Case

An eight-year-old ambulatory male patient GMFC III was found to have an increasing hip subluxation and acetabular dysplasia despite continued progress with a posterior walker and a previous history at age five of bilateral hip adductor, iliopsoas, and gracilis muscles lengthening. In general, a pediatric patient of his age and GMFC level has 27% success of not developing further hip subluxation after muscle lengthenings.⁷ Upon radiographic (*Figure 1*) review, as confirmed on computed tomography scan, bilateral uncovering of the femoral heads with right acetabular dysplasia posteriorly was observed. As the patient was ambulatory, a 3D instrumented gait analysis was conducted demonstrating bilateral mild hip internal rotation, normal flexion/extension motion, and mild lurching secondary to bilateral abductor weakness and poor control (*Figure 2*).

With evidence of physical exam, radiographs, and 3D gait analysis, this child was sent to a pediatric neuromuscular-orthopedic surgeon, who performed bilateral hip femoral varus derotational osteotomies with right acetabuloplasty (*Figure 3*). Imaging and clinical findings dictated preoperative planning for PFOs. The patient was in the supine position

Figure 1. Preoperative X-Ray Showing CP-Caused Hip Dysplasia in Supine Position. Anterior to Posterior (Front to Back) X-Ray Displaying Hip Dysplasia in the Right Hip (at the Orange Arrow). The Dotted Red Lines Show the Shortage of Acetabular Coverage in the Dysplastic Hip vs. the Healthy Hip.

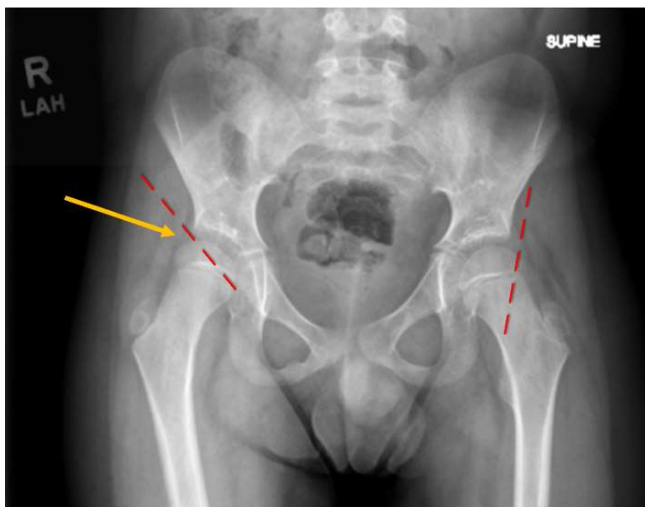
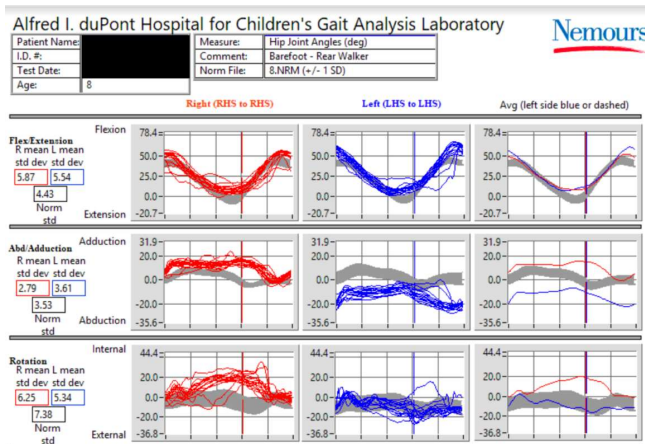
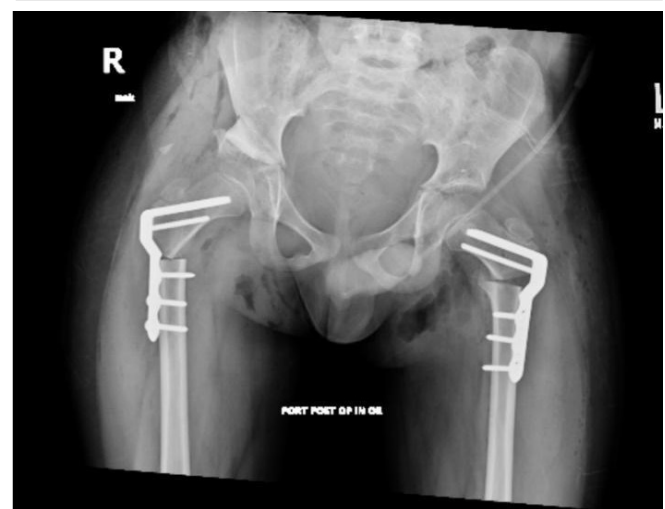

Figure 2. 3D Instrumented Gait Analysis of Hip Motion During Ambulation for an 8-Year-Old Boy GMFC III with CP. The Patient is Seen with Out-of-Range Motion Compared Against Normal Standard Deviations.



during surgery; the patient's position and closure are the same in most PFOs. The 5 cm long incision was laterally originating at the tip of the greater trochanter. The femoral osteotomy goal was to provide a medially based closing wedge osteotomy. The aim was to improve the hip's centering by restoring the femoral neck and head by decreasing (varus) the femoral neck-shaft angle. Internal fixation commonly requires an ABP or the LCP (Locking Cannulated Blade System). LCP supplies primary strength by locking screws on a plate and deviation of femoral neck screws and involves guidewires. The guidewire for the blade plate chisel was inserted into the femoral neck along its axis. Since the varus correction was conducted at 30° with a 110° plate, the guidewire was placed by adjusting the instruments to 140°. After placing the child-size chisel, due to fluoroscopy, particularly in the lateral intraoperative view, the lateral femur was too small and unable to accommodate the adolescent 4.5 mm cannulated system. The medially based femoral wedge osteotomy was performed; the OP plate was then placed into the proximal fragment without difficulty, and the osteotomy was reduced, assuring bilateral symmetry of length and rotation, affixed to the femur. Final intraoperative radiography was satisfactory upon completing all procedures, including pelvic osteotomy of the right hip for adequate bilateral hip reconstruction.

Figure 3. Immediate Postoperative X-Ray After Initial Hip Surgery. The Bones Have Been Spliced and Conjoined with LCP.



The patient tolerated the procedure and was admitted for a 6-week course of inpatient rehabilitation. His full weight-bearing status was tolerated immediately in postoperative conditions; after one year of the surgery, osteotomies were healed, and no complaints were reported with his ambulatory functional level maintained (*Figure 4*). Due to his young age at the time of implantation, the initial plan was to remove the implants at one year postoperative. At the one-year postoperative clinic visit, the parents were unclear if there were any painful symptoms from the hardware prominence due to the child's limited communicative ability. According to the patient's mother, in retrospect, he had a vague thigh pain as he would point anteriorly or laterally to his thighs intermittently after more extended periods of walking and upright activities. The family proceeded with outpatient surgical hardware removal at 18-months postoperative with intraoperative findings marked with significant trochanteric bursitis bilaterally and symmetric bilateral loosening of shaft screws (*Figure 5*). The child subsequently tolerated the hardware removal without any complications, returning to his previous functional level, pain-free.

Discussion

The treatment of hip contractures caused by cerebral palsy was first published in 1880.⁸ A retrospective review indicates a lateral dislocation (partial) and subluxation of the hip existing in 30-60% of non-ambulatory

Figure 4. Radiograph at 18-Months in Postoperative, the Patient Displays Healed Osteotomies; The Distal Femoral Shaft Screws Are Backing Out Bilaterally.

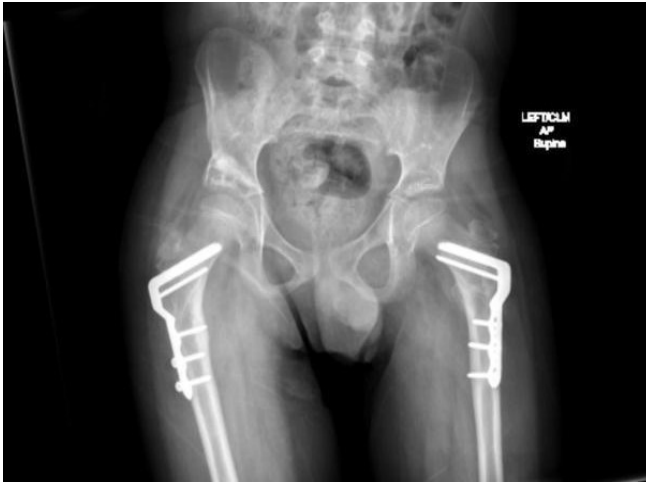
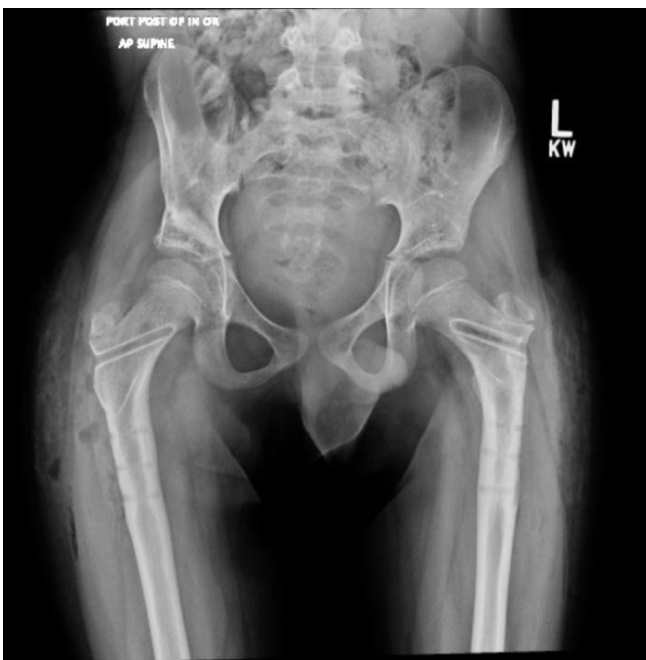
Figure 5. Postoperative X-Ray After Implant Removal.



ambulatory pediatric CP patients aged five years.⁹ The patient presented in this case was of GMFCS level III, thus using an assistive device for his ambulation. Being an ambulatory child with a gait abnormality, notable lurching, and a combination of poor motor control and along with movements of the iliotibial band abductor complex, the smaller nature of the 3.5 mm system over a 4.5 mm stronger plate setup may have led to mechanical implant loosening after femoral osteotomies healed.

The standard protocol is to determine the level of dislocation or subluxation of the hip joint using an anteroposterior radiograph, as used in this case, to measure hip migration percentage. While this case may not have involved many patients, the surgical and radiographic procedures were standard. The pelvic and hip positions during radiography were consistent with verifying the reliable change. In previous cases, the migration rate often indicated the level of risk—a

7% annual migration corresponded with a developing hip disability. A displacement between 33% and 80% indicates hip subluxation, and over 80% indicates hip dislocation. The interconnection between hip migration and migration percentage is relatively vague, and migration percentage is not uniformly indicative of a child's clinical and functional picture, which eventually plays a significant role in treatment plans. A bilateral check on hip integrity after an intervention is suggested; bilateral functionality and pain-free range of motion (ROM) have always acted as the benchmark for surgical success. In ambulatory children with notable symptoms of internally rotated gait secondary to internal rotation at the hip, the prodigal time for reconstruction is between 5 and 7 years.¹⁰ The risk of establishing recurrent bony anteversion is much lower around that age range; furthermore, motor control, planning, and balance start to reach their peak at this range. This peak allows for full restoration of function by formal elementary education, crucial to middle childhood.¹⁰

While CP and hip deformity are commonly treated conditions, the surgeon utilized a relatively newer but proven effective surgical hip fixation method. Dating back to the time of Hippocrates, osteotomies are generally performed for two reasons: to precisely realign a bone's axis or to allow bone transport.¹¹ As used in this case, a simple osteotomy may fix rotational or angular defects by which healing is in compression. This procedure solely depends on stability to encourage union in the postoperative position. As mentioned earlier, PFOs are mostly performed with fixed angled blade plates (ABP) due to proven success rate and lower cost. Despite its positive results, ABP is technically challenging for those accustomed to the implant and requires experienced attention. In this patient's case, the surgeon utilized the 3.5 mm instrumentation for a child-size implant, which worked sufficiently for the surgery but may not have loosened if a similar child-size blade plate system of 4.5 mm screws was implanted. OP-LCPs are relatively more expensive than ABPs; however, LCPs are better for steadiness, angle correction, and in training institutions in treatment of neurological hip disorders, such as CP.¹² Based on the results of this case, we conclude that both the ABP and OP-LCP systems are fruitful and safe for internal corrections of PFOs (Table 1). Additionally, the OP-LCP system may aid the residents in learning the procedure with higher confidence, fewer technical inaccuracies, and refined outcomes; this case brings caution to using this system in all hip deformities of ambulatory children. OP-LCP is exclusively targeted for the surgical correction of pediatric hip deformity, fixed knee flexion deformity, and trauma. The system acts as a primary exposure to osteotomies for trainees via easy-to-use locking screws in the proximal and distal fragments. OP-LCP employs various offsets to restore the mechanical axis of the lower limb, allowing the surgeons to use unique methodology but produce reproducible results. Finally, the implant removal difficulty level must be cautiously reviewed when selecting a method of performing pediatric PFOs. Removal of all blade plates requires attention, knowing there is a high prevalence of fractures and retained hardware in children with CP.¹³ The removal of the OP-LCP, in this case, was safely performed and extracted without morbidity, which is supported by previous literature.

Table 1. Procedural Comparison Between ABP and OP-LCP Methods.

| Step | ABP | OP-LCP |
|---------------------|---|---------------------------------------|
| Guidewire insertion | approximated to line of the seating chisel | precise to line of the seating chisel |
| Chisel insertion | below guidewire, which serves only as a reference plane | directly over the wire |
| Implant insertion | approximate and adjustable | plannable, predictable, and precise |

References

- Centers for Disease Control and Prevention. Data and Statistics for Cerebral Palsy. Available from: <https://www.cdc.gov/ncbddd/cp/data.html>. Last updated Apr 30, 2019; cited Aug 4, 2020.
- International Hip Dysplasia Institute. Developmental Dysplasia of the Hip (DDH). Available from: <https://hipdysplasia.org/developmental-dysplasia-of-the-hip/>. Last updated Jul 4, 2020; cited Aug 4, 2020.
- International Hip Dysplasia Institute. FAQ #4 What Are Some Signs I Can Look for if I Suspect I Have Hip Dysplasia? Available from: <https://hipdysplasia.org/developmental-dysplasia-of-the-hip/faq/#:~:text=Hip%20dysplasia%20that%20needs%20treatment,common%20n%20girls%20than%20boys>. Last updated Jul 4, 2020; cited Aug 4, 2020.
- Soo B, Howard JJ, Boyd RN, Reid SM, Lanigan A, Wolfe R, et al. Hip displacement in cerebral palsy. *J Bone Joint Surg Am.* 2006 Jan;88(1):121-9.
- Dyson PH, Lynskey TG, Catterall A. Congenital hip dysplasia: problems in the diagnosis and management in the first year of life. *J Pediatr Orthop.* 1987 Oct;7(5):568-74.
- Miller, F. Cerebral palsy. 1st ed. New York: Springer-Verlag; 2005.
- L. Zhou, M. Camp, A. Gahukamble, K. L. Willoughby, M. Harambasic, C. Molesworth, et al. Proximal femoral osteotomy in children with cerebral palsy: the perspective of the trainee. *J Child Orthop.* 2017 Jan;11(1):6-14.
- Reimers J. The stability of the hip in children. A radiological study of the results of muscle surgery in cerebral palsy. *Acta Orthop Scand Suppl.* 1980 Dec;51Suppl184:S1-100.
- Shore B, Spence D, Graham H. The role for hip surveillance in children with cerebral palsy. *Curr Rev Musculoskelet Med.* 2012 Jun;5(2):126-34.
- Kazemi SM, Minaei R, Safdari F, Keipourfard A, Forghani R, Mirzapourshafiei A. Supracondylar Osteotomy in Valgus Knee: Angle Blade Plate Versus Locking Compression Plate. *Arch Bone Jt Surg.* 2016 Jan;4(1):29-34.
- Dabis J, Templeton-Ward O, Lacey AE, Narayan B, & Trompeter A (2017). The history, evolution and basic science of osteotomy techniques. *Strategies in trauma and limb reconstruction.* 2017 Oct 06;12(3):169-80.
- Khoury N, Khalife R, Desailly E, Thevenin-Lemoine C, Damsin JP. Proximal femoral osteotomy in neurologic pediatric hips using the Locking Compression Plate. *J Pediatr Orthop.* 2010 Dec;30(8):825-31.
- Pountney T, Green EM. Hip dislocation in cerebral palsy. *BMJ.* 2006 Mar 30;332(7544):772-5.

Acknowledgments

The authors acknowledge Nemours/Alfred I. duPont Hospital for Children, United States.

Conflict of Interest Statement & Funding

The Authors have no funding, financial relationships or conflicts of interest to disclose.

Author Contributions

Conceptualization, Methodology, Project Administration, Visualization, Writing – Original Draft, & Writing – Review and Editing: AH & JPS. Investigation, Resources, & Supervision: JPS.

Cite as

Nahian A, Sees JP. 8-Year-Old Child with Cerebral Palsy Treated with Pelvic Osteotomies Using 3.5 mm Blade Plate Having Subsequent Bilateral Implant Aseptic Loosening: A Case Report. *Int J Med Students.* 2021 Jan-Apr;9(1):52-5.

This work is licensed under a [Creative Commons Attribution 4.0 International License](https://creativecommons.org/licenses/by/4.0/)

ISSN 2076-6327

This journal is published by the [University Library System](https://www.library.pitt.edu/), [University of Pittsburgh](https://www.library.pitt.edu/) as part of the [Digital Publishing Program](https://www.library.pitt.edu/) and is co-sponsored by the [University of Pittsburgh Press](https://www.library.pitt.edu/).

